



## Effects of Mannan Oligosaccharide and *Saccharomyces cerevisiae* on Gut Morphology of Broiler Chickens

**Veena Pani Padihari, Sita Prasad Tiwari\*, Tarini Sahu, Manoj Kumar Gendley and Surendra Kumar Naik**

*Department of Animal Nutrition, College of Veterinary Science & Animal Husbandry, Anjora, Chhattisgarh Kamdhenu Vishwavidyalaya, Durg, Chhattisgarh 491 001 India*

\*Corresponding author's email: drsptiwari@gmail.com

Received: 14 Jul. 2014

Accepted: 11 Sep. 2014

### ABSTRACT

150 day old Vencobb broiler chicks were randomly allocated to 5 treatment groups with 3 replicates of 10 chicks in each to determine the effect of mannan oligosaccharide (MOS) and *Saccharomyces cerevisiae* in gut morphology of broilers. The trial lasted for 6 weeks. For microscopic examination the representative samples of each segment of intestine were collected and fixed in the 10% buffered formalin. No significant difference was observed in treatments at length of different segments of intestine and villus height/crypt depth ratio. Significant ( $P < 0.05$ ) difference observed for the mean height of the duodenum, jejunum, and ileum villus amongst different dietary treatments, being highest in  $T_5$  and lowest in  $T_2$ . Mean crypt depth of the duodenum and ileum villus also differed significantly ( $P < 0.05$ ) amongst treatments. The highest mean crypt depth in the duodenum was recorded in  $T_5$  and lowest in  $T_2$  whereas the highest mean crypt depth of caecum was recorded in  $T_3$  and the lowest in  $T_1$ . Thickness of tunica muscularis was significantly ( $P < 0.05$ ) decreased in all segments of intestine except colorectum as MOS and *S. cerevisiae* added to the diet. Height of the epithelium of villi differed significantly ( $P < 0.05$ ) amongst treatments in all segments of intestine except caecum being maximum in  $T_5$  and minimum in  $T_2$ . It was concluded that supplementation of MOS and *S. cerevisiae* improves the gut health of broiler chickens.

**Keywords:** Broilers, Gut, Mannan oligosaccharide, *Saccharomyces cerevisiae*

### INTRODUCTION

With rising consumer demand of safer animal products, there is a widespread discouragement on the use of antibiotics due to increase bacterial resistance and the presence of antibiotic residue in animal products. Therefore the use of prebiotics and probiotics is a possible way to improve performance and intestinal health of birds without antibiotics.

Probiotics are culture of live microorganisms, which have beneficial effects on the animal health when adequately administered (Hamilton *et al.*, 2003) whereas, prebiotic is a non-digestible food ingredient which beneficially affects the host by improving the host's microbial balance (Gibson and Roberfroid, 1995). Dietary supplementation of Mannan Oligosaccharide (MOS) caused inhibition of colonization of pathogenic bacteria to gut lining (Benites *et al.*, 2008). Dietary supplementation of *Saccharomyces cerevisiae* to rabbits affected the morphology of the duodenum by increasing the total mucosa, villus height and the gland depth with inducing enlargement of the Brunner's glands (Peker *et al.*,

2014). Combination of probiotics and prebiotics namely synbiotic (Collins and Gibson, 1999) improves the viability of probiotic microorganisms, as they utilize prebiotics as a fermentation substrate (Bengmark and Bengmark, 2001). Therefore, the objective of the present study was to determine the effect of MOS and *S. cerevisiae* individually and in combination as dietary probiotic, prebiotic and synbiotic sources on gut morphology of broiler chickens.

### MATERIAL AND METHODS

#### Housing and management

The experiment was conducted in the Department of Animal Nutrition, College of Veterinary Science and Animal Husbandry, Anjora, Durg (C.G.). 6 weeks feeding trial was carried out on 150 day old Vencobb broiler chicks housed under the deep litter system, in a well-ventilated room with standard management practices. The chicks were weighed individually and randomly allocated to 5 treatment groups with 3 replicates of 10 chicks each.

## Treatment and additives

Ingredient and nutrients composition of diets for chicks at 0 to 42 days old were based on the National Research Council (NRC, 1994) recommendations. Five isonitrogenous and isocaloric diets were formulated. The different dietary treatments were include: Control diet without MOS and *S. cerevisiae* (T<sub>1</sub>); Negative control (T<sub>2</sub>); Control diet with MOS @ 500 g/ton feed (T<sub>3</sub>); Control diet with *S. cerevisiae* @ 500 g/ton feed (T<sub>4</sub>); Control diet with MOS and *S. cerevisiae* @ 500g/ton feed each (T<sub>5</sub>). In the control group premix is added, whereas in the treatments no supplements of premix should be given.

## Measurements

The birds were slaughtered by 'Halal' method at the end of the experiment. Soon after opening of carcass the whole intestine was separated and after removing the intestinal content and then regional length of different segments of intestine was recorded *i.e.* duodenum (Pancreatic loop), jejunum (from the pancreatic loop to Meckel's diverticulum), ileum (from Meckel's diverticulum to ileocaecal junction), caecum (left and right) from blind end to caeco-colic orifice and colorectum (from caeco-colic orifice to cloaca) by ruler. For microscopic examination the representative samples of each segment of intestine were collected and fixed in the 10% buffered formalin. The tissue samples were processed in acetone-benzene sequence (Lillie and Fullmer, 1978) embedded and blocked in the paraffin. Four to eight micrometer thick transverse section were cut and stained with haematoxylin and eosin (Drury and Wallington, 1980). Following parameters were

recorded: Height of the villi, crypt depth, villus height/crypt depth ratio, height of epithelium of the villi and thickness of the Tunica muscularis.

## Statistical analysis

For interpretation of the results the data were subjected to Complete Randomized Block Design method as suggested by Snedecor and Cochran (1994).

## RESULTS AND DISCUSSION

No significant difference was observed amongst treatments at length of different segments of the intestine due to dietary supplementation of MOS and *S. cerevisiae* (Table 1). Significant (P<0.05) difference observed for the mean height of the villi of duodenum, jejunum, and ileum amongst different dietary treatments, being highest in T<sub>5</sub> and lowest in T<sub>2</sub> whereas it was not significant for caecum and colorectum (Fig. 1). The findings were in accordance with Loddi *et al.* (2002) and Santin *et al.* (2001) who observed that MOS and *S. Service* improves gut health of chickens as indicated by the increase villus height. Increased villus height is correlated with an increased digestive and absorptive function of the intestine (Pluske, 1996) and activation of cell mitosis (Samanya and Yamuchi, 2002).

Hence, present findings support the hypothesis that MOS and *S. cerevisiae* stimulate the intestinal villus development by increasing cell proliferation. However, Yang *et al.* (2007) and Brümmer *et al.* (2010) reported that MOS supplementation does not affect the gut morphology in chickens.

**Table 1.** Effect of MOS and *S. cerevisiae* on length of different segments of intestine of broiler chickens as percent length of total intestine

Particulars	T <sub>1</sub>	T <sub>2</sub>	T <sub>3</sub>	T <sub>4</sub>	T <sub>5</sub>
Duodenum	19.1±0.37	21.4±0.68	21.16±0.38	19.77±0.18	18.73±0.33
Jejunum	83.2±1.21	83.63±0.95	83.6±0.76	81.86±1.43	84.7±0.81
Ileum	12.2±0.23	12.26±0.27	12.93±0.24	12.06±0.37	11.6±0.60
<b>Caecum</b>					
Left	15.4±0.32	15.26±0.20	14.80±0.34	15.5±0.45	16.1±0.17
Right	15.1±0.47	15.2±0.20	16.03±0.12	15.33±0.38	15.1±0.43
Colorectum	11.07±0.53	9.93±0.20	9.9±0.25	9.8±0.26	10.06±0.49

T<sub>1</sub> = Control, T<sub>2</sub> = Negative control T<sub>3</sub> = Control diet with MOS @ 500 g/ton feed, T<sub>4</sub> = Control diet with *S. cerevisiae* @ 500 g/ton feed, T<sub>5</sub> = Control diet with MOS and *S. cerevisiae* @ 500g/ton feed each

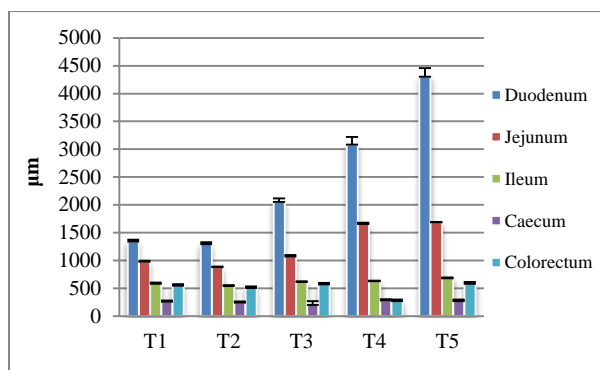
Mean crypt depth of the villi of the duodenum and ileum also differed significantly (P<0.05) amongst treatments, whereas it was non-significant for jejunum, ileum and colorectum. The highest mean crypt depth in the duodenum was recorded in T<sub>5</sub> and lowest in T<sub>2</sub> whereas the highest mean crypt depth of caecum was recorded in T<sub>3</sub> and the lowest in T<sub>1</sub> (Fig. 2). No significant difference was observed in the villus height and crypt depth ratio (Fig. 3). Thickness of tunica muscularis was significantly (P<0.05) decreased in all segments of intestine except colorectum as MOS and *S. cerevisiae* added in the diet. In the duodenum, jejunum, ileum and caecum lowest thickness obtained in T<sub>5</sub> group, however, there was significant (P<0.05) increase in T<sub>2</sub> group (Fig. 4). Height of epithelium of villi differed significantly (P<0.05) amongst treatments in all segments of intestine excluding caecum and maximum height noticed in T<sub>5</sub> and minimum in T<sub>2</sub>

group (Fig. 5). Present findings were similar with other workers (Gunal *et al.*, 2006 and Samanya and Yamuchi, 2002). Gunal *et al.* (2006) also observed that probiotic supplementation decreases muscularis thickness in jejunum and ileum. Present findings revealed changes in epithelial height which are indicative of cellular proliferation and intercellular activities. Intestine can change its surface by increasing or decreasing length and the height of villi (Zikic *et al.*, 2008).

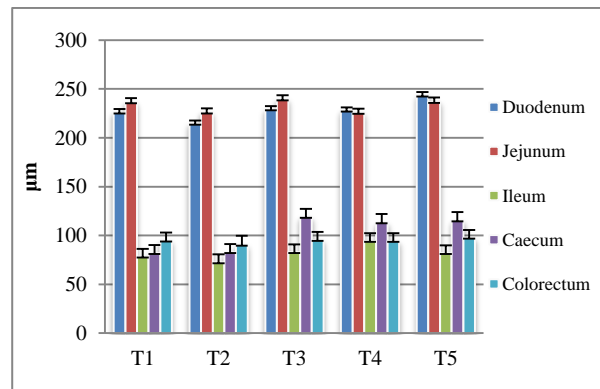
Greater surface area of small intestine is critical for appropriate digestive function and should be covered with long healthy villi. For protection of the intestinal villi, the gut produces protecting mucus which is secreted from goblet cells. Baurhoo *et al.* (2009) observed that goblet cell numbers were increased with dietary MOS. A shallow crypt is an indicator for capability of small intestine which requires less nutrients for regeneration and subsequently allows the

intestinal cells to produce more digestive enzyme and better nutrient absorption. Production of enzymes like maltase, leucine aminopeptidase, and alkaline phosphatase increased with MOS supplementation. It has been also reported that energy digestion was better when including MOS in broilers diet (Yang *et al.*, 2008).

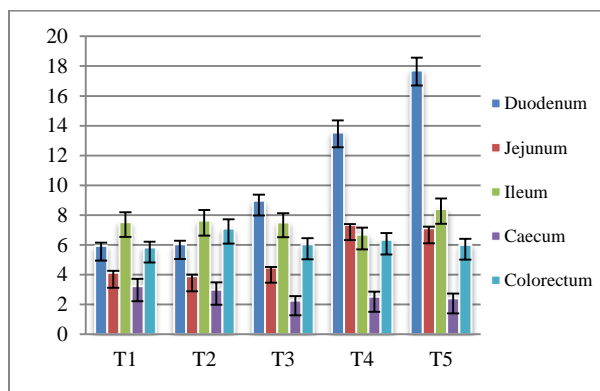
Obtained results in current experiment confirmed that supplementation of prebiotics and probiotics alters the morphology of gastrointestinal tract. These changes were depicted by elongation of villi and increased villi/crypt ratio, which indicate a lower rate of enterocyte-cell migration from the crypt to the villus. Abudabos and Yehia (2013) reported that dietary MOS improves the broiler gut health and function which can serve as a safe alternative to antibiotic growth promoter.



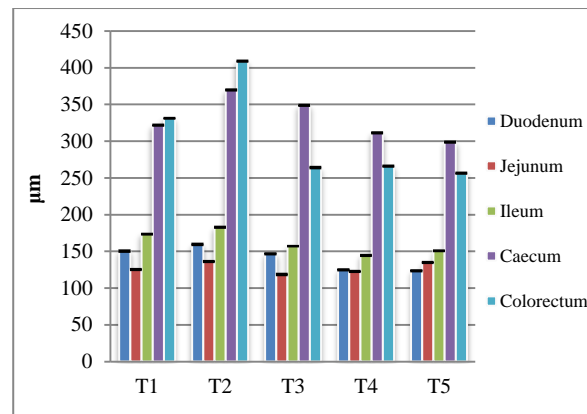
**Figure 1.** Effect of MOS and *S. cerevisiae* on height of villi in broiler chickens



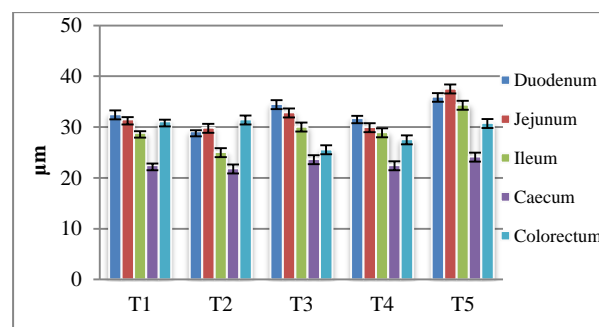
**Figure 2.** Effect of MOS and *S. cerevisiae* on crypt depth of villi in broiler chickens



**Figure 3.** Effect of MOS and *S. cerevisiae* on villi height/crypt depth ratio in broiler chickens



**Figure 4.** Effect of MOS and *S. cerevisiae* on thickness of tunica muscularis in broiler chickens



**Figure 5.** Effect of MOS and *S. cerevisiae* on height of epithelium of villi in broiler chickens

## CONCLUSION

In conclusion, supplementation of MOS and *S. cerevisiae* improves the gut health of broiler chicken by increasing intestinal length, villi height, crypt depth: villi height ratio and decreasing the thickness of tunica muscularis.

## Acknowledgement

The authors are highly thankful to Dean, College of Veterinary Science and Animal Husbandry, Anjora, Durg (Chhattisgarh), INDIA, for providing the financial and other required facilities to accomplish the study.

## REFERENCES

- Abudabos AM and Yehia HM (2013). Effect of dietary mannan oligosaccharide from *Saccharomyces cerevisiae* on live performance of broilers under *Clostridium perfringens* challenge. Italian Journal of Animal Science, 12 (2).
- Baurhoo B, Ferket PR and Zhao X (2009). Effects of diets containing different concentrations of manna oligosaccharide or antibiotics on growth performance, intestinal development, cecal and litter microbial populations, and carcass parameters of broilers. Poultry Science, 88 (11): 2262–2272.
- Bengmark S and Bengmark S (2001). Pre-pro-and synbiotics. Current Opinion in Clinical Nutrition and Metabolic Care, 4: 571-579.

- Benites V, Gilharry R, Gernat AG and Murillo JG (2008). Effect of dietary Mannan Oligosaccharide from Bio-Mos or SAF-Mannan on live performance of broiler chickens. *Journal of Applied Poultry Research*, 17: 471-475.
- Brümmer M, Jansen van Rensburg C and Moran CA (2010). *Saccharomyces cerevisiae* cell wall products: the effects on gut morphology and performance of broiler chickens. *South African Journal of Animal Science*, 40:14-21.
- Drury RAB, Wallington EA and Cameron SR (1967). In: Carleton's Histological Techniques. 4<sup>th</sup> Edition. Oxford University Press, New York.
- Gibson GR and Roberfroid MB (1995). Dietary modulation of the human colonic microbiota: Introducing the concept of prebiotics. *Journal of Nutrition*, 125: 1401-1412.
- Gunal M, Yayli G, Kaya O, Karahan N and Sulak O (2006). The Effect of Antibiotic Growth Promoter, Probiotic or Organic Acid Supplementation on Performance, Intestinal Microflora and Tissue of Broilers. *International Journal of Poultry Science*, 5(2): 149-155.
- Hamilton SR, Bobrowicz P, Bobrowicz B, Davidson RC, Li H, Mitchell T, Nett JH, Rausch S, Stadheim TA, Wischnewski H, Wildt S and Gerngross TU (2003). Production of complex human glycoproteins in yeast. *Science*, 301: 1244-1246.
- Lillie RD and Fullmer HM (1976). In: *Histopathologic Technic and Practical Histochemistry*. 4th edition. New York: McGraw-Hill: 193-197.
- Loddi MM, Nakaghi LSO, Edens F, Tucci FM, Hannas MI, Moraes VMB and Arika J (2002). Proc. 11th European Poult. Sci. Conf., Bremen, Germany. Sept. 6-10.
- NRC (1994) National research council. *Nutritional Requirements of Poultry*. 9<sup>th</sup> revised edition. National Academy Press, Washington D. C.
- Peker S, Seyidoğlu N, Galip N and Zik (2014). The Effect of *Saccharomyces cerevisiae* on the Morphological and Histochemical Characteristics of the Duodenal Mucosa in the Rabbit. *Kafkas Univ Vet Fak Derg*, 20 (1): 87-92.
- Pluske JR, Thompson MJ, Atwood CS, Bird PH, Williams LH and Hartmenn PE (1996). Maintenance of villus height and crypt depth, and enhancement of disaccharide digestion and monosaccharide absorption, in piglets fed on cows' whole milk after weaning. *British Journal of Nutrition*, 76: 409-422.
- Samanya M and Yamauchi K (2002) Histological alterations of intestinal villi in chickens fed dried *Bacillus subtilis* var. *natto*. *Comparative Biochemistry and Physiology*, 133:95-104.
- Santin E, Maiorka A, Macari M, Grecco M, Sanchezi JC, Okada TM and Myasaka AM (2001). *Journal of Applied Poultry Research*, 10: 236-244.
- Snedecor GW and Cochran BW (1994). *Statistical Methods*. 8<sup>th</sup> Edn. Iowa State University Press, Ames, Iowa.
- Yang Y, Iji PA, Kocher A, Mikkelsen LL and Choct M (2007). Effects of mannanoligosaccharide on growth performance, the development of gut microflora and gut function of broiler chickens raised on new litter. *Journal of Applied Poultry Research*, 16: 280-288.
- Yang Y, Iji PA, Kocher A, Thomson E, Mikkelsen LL and Choct M (2008). Effects of mannanoligosaccharide in broiler chicken diets on growth performance, energy utilisation, nutrient digestibility and intestinal microflora. *British Poultry Science*, 49 (2): 186-194.
- Žikić D, Perić L, Ušćebrka G, Stojanović S, Milić D and Nollet L (2008). Effect of prebiotics in broiler breeder and broiler diets on performance and jejunum morphology of broiler chickens. 1st Mediterranean Summit of WPSA, Book of Proceedings, Porto Carras, Greece: 879-882.