



## Evaluation of the Possible Hypolipidemic Properties of Quail Egg on Alloxan-Induced Diabetic Rats

Patrick, Emeka Aba<sup>1\*</sup> and Jonas, Anayo Onah<sup>2</sup>

<sup>1</sup>Department of Veterinary Physiology and Pharmacology, University of Nigeria, Nsukka, Enugu State, Nigeria

<sup>2</sup>Department of Veterinary Surgery, University of Abuja, Nigeria

\*Corresponding author's Email: Patrick.aba@unn.edu.ng

Received: 06 Nov. 2015

Accepted: 06 Dec. 2015

### ABSTRACT

This study evaluated the pancreatic histomorphometry and possible hypolipidemic effects of graded concentrations of quail egg administration on alloxan-induced diabetic rats. Thirty adult male albino rats were assigned to 5 groups of 6 rats per group. Diabetes was induced in the rats of groups 2-5 by single intraperitoneal injection of alloxan monohydrate at the dose of 160 mg/kg. Group 1 rats were not injected with alloxan monohydrate. Rats with fasting blood glucose levels above 126 mg/dl were considered diabetic. Upon establishment of diabetes, rats in groups 2-4 were treated with 30, 15 and 7.5 mg/ml of quail egg solution respectively. Rats in groups 1 and 5 were administered with 10 ml/kg distilled water. At the end of the 21 days treatment, blood samples were collected for lipid profile analyses. The rats were euthanized using chloroform anaesthesia and the pancreases were then collected for histomorphometric assessment. Results of the study revealed that rats treated with 30 mg/ml of quail egg solution showed significant ( $P < 0.05$ ) reductions in the serum levels of total cholesterol, triglyceride, low density lipoprotein and very low density lipoprotein when compared with the negative control group while high density lipoprotein was not significantly increased compared to the negative control. The pancreas of diabetic untreated rats showed immense cytoplasmic vacuolation of the islet cells while the groups treated with quail egg solution especially those treated at the 30 mg/ml showed mild degeneration of the islet cells. In conclusion, administration of quail egg solution to alloxanized rats demonstrated hypolipidemia and ameliorated lesions in the pancreas.

**Key words:** Quail Egg, Diabetic Rat, Lipid, Pancreas

### INTRODUCTION

Diabetes mellitus is a metabolic disorder characterized by hyperglycemia linked to relative or absolute lack of insulin (Lanza et al., 2001). Traditionally, Diabetes mellitus is classified into types 1 and 2 Diabetes mellitus. However, gestational and other types of diabetes have been described (WHO, 1999). Common clinical signs included polydipsia, polyuria, polyphagia, asthenia, blurred vision and delayed wound healing (WHO, 1999).

Hyperglycemia observed in Diabetes mellitus is sequel to abnormalities in the metabolism of carbohydrates, proteins and fats. The disease is associated with dyslipidemia such as hypercholesterolemia and hypertriglyceridemia (Goldberg, 2001). Dyslipidemia results from abnormalities in the functionality of lipoprotein lipase which tends to be blunt in the diabetic condition. Management of Diabetes mellitus included the use of oral

hypoglycemics, change of life style and diet modification (Kahn, 2005). The adverse side effects associated with the use of synthetic drugs in treatment of Diabetes mellitus have lead to a renewed vigor for research into anti-diabetic agents that are natural in origin.

Quail egg has been widely acclaimed as having a lot of therapeutic potentials. Howard et al. (2006), reported that quail egg may provide remedy for heart diseases, cancer, diabetes, ulcers and a whole lot of diseases. This effect of quail egg is perhaps connected to its nutritional contents such as omega-3 fatty acids, omega-6 fatty acids, selenium, choline, magnesium, potassium, iron, folic acid, zinc, phosphorus, vitamins etc (Howard et al., 2006). According to valid sources, Chinese medical practitioners have used quail eggs for thousands of years in the remedy of diseases (Astrup et al., 2008). This study was designed to investigate the

lipidemic effects of quail egg on alloxan-induced diabetic rats.

## MATERIALS AND METHODS

### Animals

Adult male Wistar albino rats of 10 to 16 weeks of age and average weight of  $160 \pm 15$  g were obtained from the animal house of the Faculty of Biological Sciences, University of Nigeria, Nsukka, Enugu state, Nigeria. The animals were acclimatized for the duration of 7 days under standard environmental conditions with 12 hours light/dark cycle maintained on a regular feed (vital feed) and water *ad libitum*.

### Quail egg

The quail eggs used were obtained from the Faculty of Veterinary Medicine, University of Nigeria, Nsukka, Enugu state, Nigeria Farm. The freshly laid eggs weighed between 10-15 g.

### Preparation of quail egg

It was done according to the method of Aba, et al., (2015). An empty beaker was weighed A (g). The shells of the quail eggs were broken with a spatula and the contents emptied into the beaker. The weight of the beaker and the contents were recorded as B (g). The weight of the contents of the egg was obtained by subtracting only the weight of the beaker from the weight of the beaker and its contents. Thus the weight of the egg yolk and albumen, C (g) was expressed mathematically thus:

$$C (g) = B (g) - A (g)$$

C (g) was solubilized in a calculated quantity of distilled water to make a desired concentration of quail egg solution and thereafter, serial dilutions of the stock solution were made for the different groups. The serial dilutions were made in such a way that the resulting concentrations were able to pass through the stomach tube used in administering the solution to the rats.

### Induction of experimental Diabetes mellitus

Diabetes was induced in rats using the method described by Venugopal et al. (1998). The rats were fasted for 16 h prior to induction of diabetes. Diabetes was induced by a single intraperitoneal injection of alloxan monohydrate at the dose of 160 mg/kg. Diabetes was established on day two post induction by the confirmation of fasting blood glucose levels above 7 mmol/l or 126 mg/dl (Venugopal et al., 1998).

### Experimental design

Thirty adult male albino Wistar rats were assigned into 5 groups of 6 rats per group. Following the establishment of Diabetes mellitus on the second day post induction, the rats were treated with different concentrations of quail egg solution as follows (Table 1).

Upon establishment of diabetes, the quail egg solution was administered orally daily for 21 days. Blood samples for assay of lipid panel were collected on the day 21. The rats were humanly euthanized using chloroform anaesthesia and the pancreases were collected for histological processing.

**Table 1.** Oral treatment of experimental rats with different concentrations of quail egg solution

Group	Treatment
1	Non diabetic rats orally administered 0 ml/kg distilled water (positive control)
2	Diabetic rats orally administered 30 mg/ml quail egg solution (highest concentration)
3	Diabetic rats orally administered 15 mg/ml quail egg solution (medium concentration)
4	Diabetic rats orally administered 7.5 mg/ml quail egg solution (lowest concentration)
5	Diabetic rats orally administered 10 ml/kg distilled water (Negative control)

### Blood collection

Blood samples were collected on day 21 from the animals into a clean sample bottle using orbital techniques and sera harvested after centrifugation, for lipid profile determinations (Parasuraman et al., 2010). Blood samples were collected from the retrobulbar plexus of the median canthus of the eye of the rats (Parasuraman et al., 2010).

### Determination of lipid profile

The serum cholesterol was determined by the cholesterol oxidase-peroxidase method (Allain et al.,

1974). High Density lipoproteins (HDL) cholesterol concentration was determined by the method of Assmann et al., (1984). Estimation of Triglyceride concentration was done by method of Albers et al., (1978).

All determinations were done using Quimca Clinica Applicada (QCA) commercial test kits (Spain). Very Low Density Lipoprotein (VLDL) and Low Density Lipoprotein (LDL) cholesterol concentration, were calculated using Friedwald formular (Friedwald et al., 1972).

### Histopathological examination

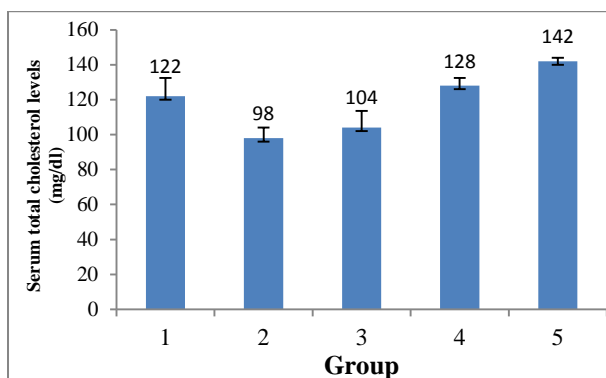
The histological examinations of the pancreas tissues of Wistar male albino rats were done using the method of Drury et al., (1967). The tissues were stained with Haematoxylin and Eosin dyes.

### Statistical Analysis

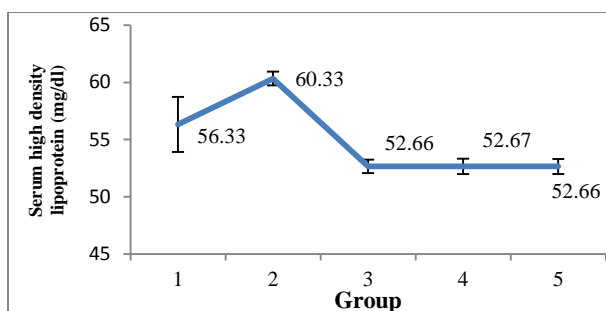
Data obtained were analyzed using One-way Analysis of Variance (ANOVA). Variant means were separated using Duncans Multiple range Post hoc Test. P values  $\leq 0.05$  were considered significant. Results were presented as Mean  $\pm$  Standard Error of the Mean (Mean  $\pm$  SEM).

### RESULTS

Effects of quail egg solution administration on serum total cholesterol levels of alloxan-induced diabetic male rats indicated that the serum total cholesterol concentration of rats in group 2 was significantly ( $P < 0.05$ ) lower than the positive and negative control rats and the other treatment groups (Diagram 1). Effects of quail egg solution on serum high density lipoprotein levels of alloxan-induced diabetic male rats showed that the serum concentrations of high density lipoprotein of the rats in group 2 were significantly higher than the positive and negative control groups (Diagram 2).

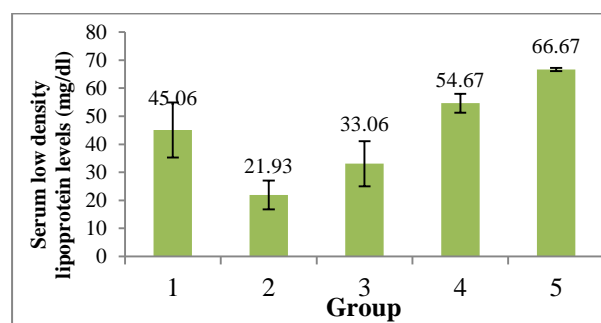


**Diagram 1.** Effects of quail egg solution administration on serum total cholesterol levels of alloxan-induced diabetic male rats

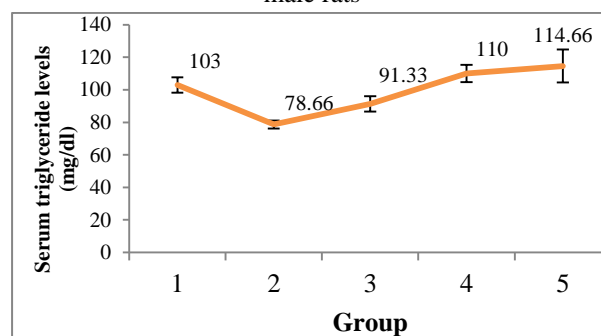


**Diagram 2.** Effects of quail egg solution on serum high density lipoprotein levels of alloxan-induced diabetic male rats

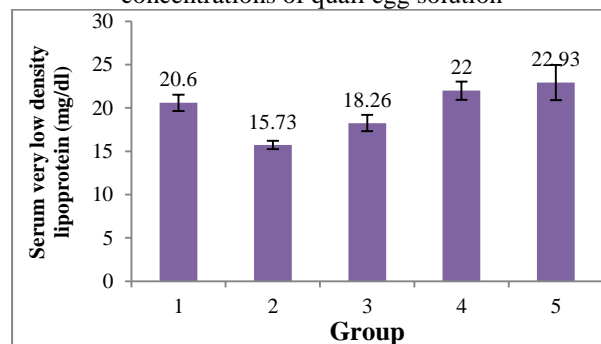
Effects of quail egg solution on serum low density lipoprotein levels of alloxan-induced diabetic male rats were that the serum low density lipoprotein concentrations in groups 1, 4 and 5 rats were statistically comparable while that of groups 2 and 3 were significantly ( $P < 0.05$ ) lower than the negative control group (Diagram 3). Serum triglyceride levels of alloxan-induced diabetic male rats treated with different concentrations of quail egg solution indicated that the triglyceride levels in group 2 was significantly ( $P < 0.05$ ) lower than the positive and negative control groups (Diagram 4). Serum very low density lipoprotein levels in alloxan induced diabetic male rats administered with quail egg solution showed that the serum very low density lipoproteins in group 2 were significantly ( $P < 0.05$ ) lower than the other treatment groups and the controls (Diagram 5).



**Diagram 3.** Effects of quail egg solution on serum low density lipoprotein levels of alloxan-induced diabetic male rats



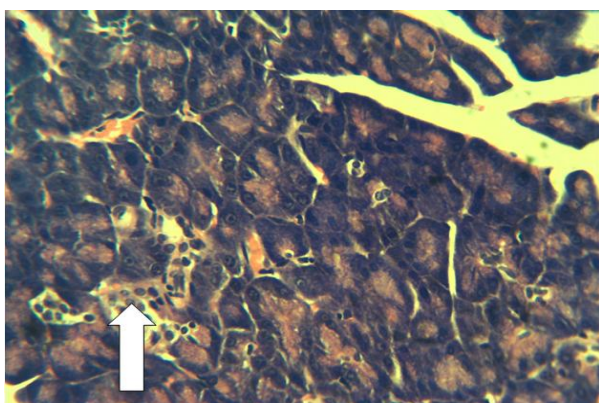
**Diagram 4.** Serum triglyceride levels of alloxan-induced diabetic male rats treated with different concentrations of quail egg solution



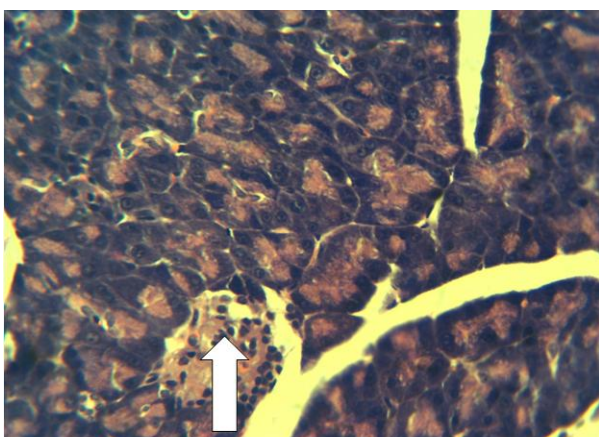
**Diagram 5.** Serum very low density lipoprotein levels in alloxan induced diabetic male rats administered with quail egg solution

Pancreas of the normal control adult male rat (Group 1) shows normal distribution of the cells of islet of langerhans. The histopathology slide showed pancreatic islets cells in adequate distribution relative to the size of the islet (Figure 1). Pancreas of diabetic rat treated with 30 mg/ml of quail egg solution (Group 2) showing adequate distribution of the islets cells of langerhans. The cells in the islets appeared to have been slightly depleted though, there were still adequate numbers of the cells present (Figure 2). Pancreas of diabetic male rat treated with 15 mg/ml of quail egg solution (Group 3) showing relatively moderate distribution of the langerhans cells. There are ongoing degeneration and necrosis of the islet cells. The cells have been therefore depleted (Figure 3). Pancreas of diabetic rat treated with 7.5 mg/ml of quail egg solution (Group 4) sparsely showing cells of the islet of langerhans; the pancreas showed severe depletion of the islets cells. Degeneration and necrosis are ongoing (Figure 4).

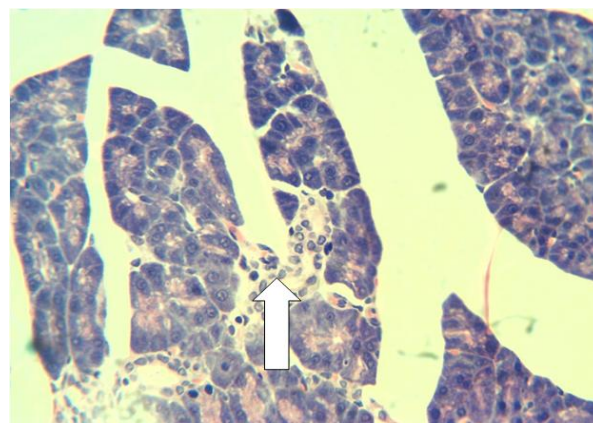
Pancreas of untreated diabetic rat (Group 5) showing severe depopulation of the cells in the islet of langerhans; the depopulation of the pancreatic islet cells here is too severe (Figure 5).



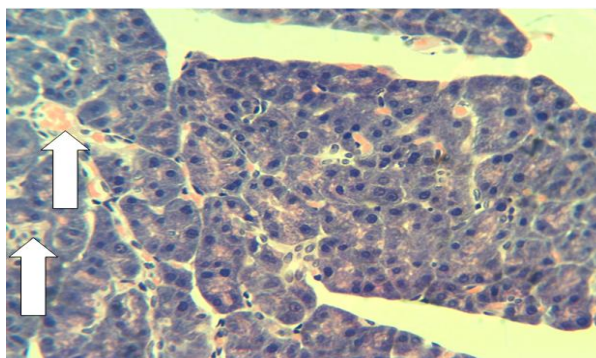
**Figure 1.** Pancreas of the normal adult male rat showing normal distribution of the cells of islets of langerhans (Arrow) (H& E x400)



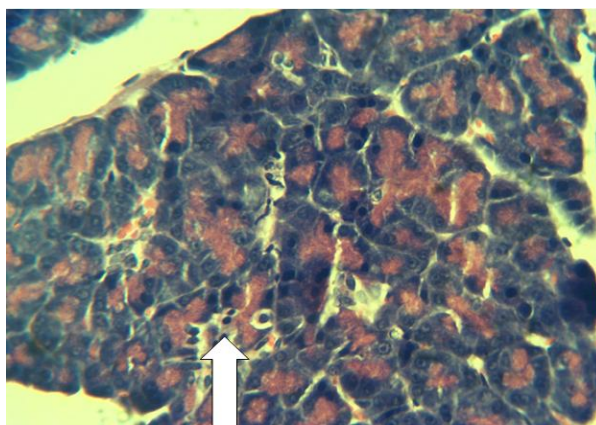
**Figure 2.** Pancreas of diabetic male rat treated with 30 mg/ml of quail egg solution showing normal distribution of the cells of islets of langerhans (Arrow) (H& E x400)



**Figure 3.** Pancreas of diabetic male rat treated with 15 mg/ml of quail egg solution showing relatively moderate distribution of the langerhans cells (Arrow) (H& E x400)



**Figure 4.** Pancreas of diabetic male rat treated with 7.5 mg/ml of quail egg solution sparsely showing cells of the islets of langerhans (Arrows) (H& E x400)



**Figure 5.** Pancreas of diabetic untreated rat showing severe depopulation of the cells in the islets of langerhans (Arrow) (H& E x400)

## DISCUSSION

The significant ( $P < 0.05$ ) increases in the serum levels of total cholesterol, triglyceride, LDL, VLDL and decrease in HDL levels (Diagrams 1-5) is associated with induction of diabetes using alloxan monohydrate (Aba et al., 2014). The groups treated with quail egg revealed significant ( $P < 0.05$ ) reductions in the serum levels of total cholesterol, LDL, VLDL and increase in HDL in a concentration-dependent manner compared to

the untreated diabetic group. This hypolipidemic effect of quail eggs may be attributed to its nutritional contents such as omega-3 fatty acids and vitamins. Hypolipidemic activities of omega-3 fatty acids in diabetic patients have been previously reported (Malasanos and Stacopoole 1991). Omega-3 fatty acid exerts positive effect in pathways predisposing to arteriosclerosis. Malasanos and Stacopoole (1991) submitted that omega-3 fatty acid from fish oil administered to diabetic patients lowered serum lipids, lipoproteins and blood pressure in humans. It is also believed that the antioxidants contents such as zinc and vitamins present in quail egg may have significantly contributed to its positive effect in managing diabetes (Cruz et al., 2015). The antioxidant role of zinc in Diabetes mellitus cannot be overemphasized. Presence of zinc ameliorates diabetes by reducing hyperglycemia, enhancing phosphorylation of insulin receptors and by acting as cofactor for the superoxide dismutase (Cruz et al., 2015). Experimental evidences indicating that antioxidants are important in treating diabetes and its complications have been confirmed (Matough et al., 2012). This finding is in consonance with the reports of Omoruyi et al. (2001) who reported that any substance with antidiabetic potential must be able to increase the levels of HDL and lower LDL levels.

The results of the histomorphometry of the pancreas revealed severe decrease in the cells of islets of langerhans of the untreated diabetic group. This may be consequent upon the effect of alloxan monohydrate (Lenzen, 2008 and Szukuldeski, 2001). Treatment of the diabetic rats with quail egg solution ameliorated in a concentration-dependent manner, the destruction of the islets cells compared with the negative control group as evidenced by the histopathology slides (Figures 1-5). It is thought that this effect could have been mediated by the antioxidant properties inherent in the quail eggs. Antioxidants are known to scavenge free radicals such as reactive oxygen species thereby minimizing oxidative stress-induced injuries (Matough et al., 2012).

## CONCLUSION

It was concluded from the results of the study that administration of quail egg solution especially at the concentration of 30 mg/ml to the diabetic rats resulted in hypolipidemia.

## REFERENCES

Aba PE, Nwaigwe CU, Okwuagwu FO, Udem SC and Asuzu IU (2014). Effect of aqueous extract of *Hibiscus sabdariffa* on some biochemical parameters in alloxan-induced diabetic rats. *Comparative Clinical Pathology*,

Published online 13, Febuary 2014; DOI: 10.1007/S00580-014-1889-7.

- Aba PE, Igwebuike DC and Onah JA (2015). Effects of various concentrations of quail egg solution on glycemia and antioxidant parameters of alloxan-induced diabetic rats. *Journal of Advances in Medical and Pharmaceutical Sciences*, 5(4):1-7.
- Albers JJ, Warmick GR and Cheng, MC (1978). Determination of high density lipoprotein (HDL). *Lipids*, 13: 926-932.
- Allain CC, Poon LS, Chan, CS, Richmond W, and Fu PU (1974). Enzymatic determination of total cholesterol. *Clinical Chemistry*, 20:470-475.
- Assmann G, Jabs HU, Kohnert U, Nolte W and Schriewer H (1984). Determination of low density lipoprotein (LDL). *Clinica Chimica Acta*, 140: 77-83.
- Astrup A, Dyerberg J, Selbeck M, and Stender S (2008). Nutrition transition and its relationship to the development of obesity and related chronic diseases. *Obesity Review*, 9(1):48-52.
- Cruz K.J, De Oliveira AR, and Marreiro DN (2015). Antioxidant role of zinc in diabetes mellitus. *World Journal of Diabetes*, 6(2):333-337.
- Drury RA, Wallington A and Cameroun SR (1967). In *Carleton's Histological Techniques*. Oxford University Press, New York. Pp:1- 420.
- Friedwald WT, Levy RI, and Fredrickson DS (1972). Estimation of the concentration of low-density lipoprotein cholesterol in plasma, without use of the preparative ultracentrifuge. *Clinical Chemistry*, 18:499-502.
- Goldberg IJ (2001). Diabetic Dyslipidemia: Statins versus Fibrates in the Treatment of Diabetic Dyslipidemia. Symposium. Program and abstracts of the 61st Scientific Sessions of the American Diabetes Association; June 22-26, Philadelphia, Pennsylvania.
- Howard BV, Manson JE, and Stefanic ML (2006). Low fat dietary pattern and weight change over 7 years: the women's health initiative Dietary Modification Trial. *Journal of American Medical Association*, 295(1): 39-49.
- Kahn CM (2005). Diabetes mellitus in Kahn CM (ed) "Merck Veterinary Manual, 9<sup>th</sup> edition", Merck and Co, Inc. White House Station, NJ U.S.A 439-1013.
- Lanza RP, Eker DM, Kuhlreigber UM, Marsh JP, Ringelin J, and Chink WL (2001). Transplantation of Islets using micro encapsulation: studies in diabetic rodents and dogs. *Journal of Molecular Medicine*, 77: 206-210.
- Lenzen S (2008). The Mechanisms of Alloxan and Streptozotocin-Induced Diabetes. *Diabetologia*, 51(2): 216-226.
- Malasano TH and Stacopoole DW (1991). Biological effects of omega-3 fatty acids in Diabetes mellitus. *Diabetes care*, 14(12):1160-1179.

- Matough FA, Budin SB, Hamid ZA, Alwahaibi N and Mohamed J (2012). The role of oxidative stress and antioxidants in diabetic complications. *Sultan Qaboos University Medical Journal*, 12(1):5-18.
- Omoruyi FO, Philip BG, Helen NA, Errol Y and Morrison A (2001). Increased plasma and Liver lipids in Streptozotocin-induced diabetic rats: effects of yam (*Dioscorea caynesis*) or dasheen (*Colocassia esculenta*) extract supplements. *Diabetologia croatica*, 30(3):87-92.
- Parasuraman S, Raveendran R and Kesavan R (2010). Blood sample collection in small laboratory animals” *Journal of Pharmacology and Pharmacotherapeutics*, 1(2): 87-93.
- Szkudelski T (2001). The mechanism of alloxan and streptozotocin action in beta cells of the rat pancreas. *Physiology Research*, 56 (6): 537-546.
- Venogopal PM, Prince PSM and Pari L (1998). Hypoglycemic activities of *Syzygium cumini* seeds; effect on lipid peroxidation in alloxan diabetic rats. *Journal of Ethnopharmacology*, 61:1-7.
- WHO (1999). Definition Diagnosis and Classification of Diabetes mellitus and its complications; A Report of WHO consultation Department of Non-communicable disease surveillance Geneva, Switzerland.