



Effect of Blend Herbal Supplement on Haematology and Serum Biochemistry in Commercial Layer Chicken

Sakthi Priya Muthusamy^{1*}, Thippichettipalayam Ramasamy Gopala Krishna Murthy¹ and Vijayanand Thiagarajan²

¹Ethno Veterinary Herbal Research Centre for Poultry, Namakkal, Tamil Nadu, India

²Ventri Biologicals, Tamil Nadu, India

*Corresponding author's Email: sakthi_vet@yahoo.co.in

Received: 07 April 2017

Accepted: 11 May 2017

ABSTRACT

Many herbal supplements are tested for their efficacy in poultry to replace the antibiotic growth promoter. Hence this study was carried out to find the effect of a blend herbal preparation (*Ocimum sanctum*, *Zingiber officinale*, *Allium sativum*, *Trigonella foenum graecum* and *Curcuma longa*) on the vital parameters in layers. An experimental trial for three weeks was carried out on 80 layers aged 11 weeks. Birds were randomly divided to 4 groups with 2 replicate for each group and supplemented by herbal preparation @ 0.1 percent, 0.25 percent and 0.5 percent in feed. The results indicated a significant increase in the red blood cells count, white blood cell count, total protein, albumin, globulin, calcium, phosphorus and reduction in the enzyme aspartate aminotransferase and alkaline phosphatase with alanine aminotransferase in the normal range. The significant increase in the vital parameters, decrease in hepatic enzymes inside the clinically healthy condition denote that the birds were in good health. Birds increased nutrient utilization, improved oxygen carrying capacity and caused active immune system. The better absorption of minerals like calcium and phosphorus signifies the role of herbs in enhancing digestion performance. Oral feeding caused a normal activity of hepatic enzymes which can prove safety and hepatoprotective nature of these herbs. Therefore, it can be concluded that supplementation of these herbs in the layer feed could be important in prevention of diseases in birds. However further studies are recommended to indicate the toxic levels of these herbs and optimize the beneficial dosage in diet of layer birds.

Key words: Enzymes, Haematology, Herbs, Layers, Serum biochemistry.

INTRODUCTION

Antibiotic growth promoters in livestock and poultry production are practiced for many years to promote the growth and to improve the feeding efficiency thereby improving the health of the animal and the birds. But the inclusion of these feed additives increases not only the cost of production but also increases the development of resistant microbes and produces residues in meat and eggs (Sojoudi et al., 2012; Yang et al., 2009). In the present scenario, the use of in-feed antibiotics is under threat after the ban of the antibiotic use by the European Union since January 2006. This ban has given the increasing prevalence of resistance to antibiotics in chicken (Kabir, 2009) and escalated the search for alternatives for use in

the poultry industry (Janardhana et al., 2009). Also the recent changes in legislation on the use of antimicrobials, altered feed requirements and more efficient birds necessitate the need for an alternative treatment. Hence many International Institutions and organizations related to public health are showing deep concern to reduce the use of antibiotics in poultry (Gatne et al., 2010). World Health Organization (WHO) has started to give emphasis on the development and use of herbal products for the benefit of world population in viewing the limitations and ill effects of chemical drugs (Jinsuklee, 2004).

Currently natural alternatives like probiotics, prebiotics, plant extracts and the essential oils are gaining importance as alternative supplement (Pirogozliev et al.,

2008; Yang et al., 2008; Ayasan, 2013). The important advantages claimed of medicinal plants in various ailments are their safety besides being economical, clinically effective and their easy availability. Medicinal plants compete with synthetic drugs and most of them do not have any residual effects (Tipu et al., 2006). Many herbal plant preparations are prescribed to strengthen host resistance (Thatte and Dahanakur, 1989) due to their immunomodulatory activities. Immunity breakdown will make the harmful bacteria to take upper hand as the gastro intestinal tract microflora is a mixture of fungi, protozoa and bacteria comprising both beneficial and harmful microorganisms (Gabriel et al., 2006). Harmful bacteria may be involved in localized or systemic infections, intestinal putrefaction, and toxin formation (Jeurissen et al., 2002). Hence, to get rid of the mortality associated with harmful luminal pathogens viz., *Salmonella*, *Escherichia coli* (*E.coli*), *Clostridium* sp. and other pathogenic bacteria and to improve the gut health, modulate the immune response and to aid in digestion and absorption herbal extracts can be used as an alternative treatment.

Cardelle et al. (2010) stated that the *Allium sativum* (garlic) exerts a differential inhibition between beneficial intestinal microflora and potentially harmful enterobacteria. Bharkava et al. (2012) reported that *Zingiber* (Zinger) contain potent antimicrobial property against *E.coli*, *Pseudomonas aeruginosa*, *Staphylococcus aureus*, *Enterococcus faecalis*. Ashish et al. (2013) investigated the methanol and aqueous extract of *Ocimum sanctum* (tulsi) for antimicrobial activity on *E.coli*, *Proteus mirabilis* and *Staphylococcus aureus* and found that *E.coli* and *Proteus mirabilis* were resistant to both the extracts, with *Staphylococcus aureus* sensitive to both the extracts. *Trigonella foenum-graecum* (fenugreek) seeds have been reported to possess immunomodulatory, antibacterial, anti-inflammatory, antioxidant, antinociceptive, gastroprotective and anxiolytic properties (Virupaksha et al., 2007). Basu et al. (2009) proved that the fenugreek was found to strongly inhibit the growth of *Staphylococcus aureus* and *Pseudomonas aeruginosa* in *in vitro* studies. Deshmukh (2014) investigated the effect of *Curcuma longa* (turmeric) against enteric pathogens. The study showed that *E.coli*, *Enterobacter aerogenes*, *Pseudomonas aeruginosa*, *Staphylococcus aureus*, *Staphylococcus epidermidis* and *Salmonella typhimurium* were very much sensitive to turmeric extract as compared to other tested pathogens. He also concluded that the turmeric possesses curcumin, which is responsible for antibacterial activity of turmeric.

Hence the present study was taken to assess the effect of *Ocimum sanctum*, *Allium sativum*, *Curcuma longa*, *Trigonella foenum graecum* and *Zingiber officinale* on haematology and serum biochemistry on supplementation in feed as several reports are available indicating the role of these herbs in immunomodulatory, growth promoting, antibacterial, anti-cancerous, anti oxidant, anti-inflammatory, hepatoprotective and antioxidant properties (Reuter et al.,1996; Rivlin, 2001; Vijayalakshmi et al., 2011; Shukla, et al., 2012).

MATERIALS AND METHODS

The present study was carried out at a private layer farm at Pudhur, Vaiyappamali, Thiruchengodu taluk of Namakkal district, Tamil Nadu, India. A total of 80 Lohman breed layers aged 11 weeks and in the weight range of 751.67 ± 16.07 g were used for present study. The birds were allotted at random into four experimental groups with two replicates (10 birds per replicate), viz., Control group (Regular feed without any herbal preparation) as mentioned in table 1, Group I (Regular feed with 0.1% herbal preparation), Group II (Regular feed with 0.25% herbal preparation) and Group III (Regular feed with 0.5% herbal preparation). The trial lasted for 21 days (11-14 weeks). Proper management, necessary vaccinations (before the initiation of the trial) and good environmental conditions were maintained throughout the study period. The herbs *Ocimum sanctum* (Tulsi), *Allium sativum* (Garlic), *Zingiber officinale* (ginger), *Trigonella foenum graecum* (Fenugreek) and *Curcuma longa* (curcumin) were purchased fresh from market. Their rinds (ginger and garlic) were peeled off using knife, washed, shade dried and later ground to smooth powder and stored separately in an air tight container. 100 g of each herb was taken, blend and packed in an air tight plastic container for further use.

Haematological parameters

Blood samples were collected from wing vein of the chicken using sterile needles and syringes from both the control and the treated groups (six birds from each group) before initiation and 21 days after the initiation of the experimental trial. The blood samples were collected into well labelled and sterilized bottles containing Ethylene Diamine Tetra Acetic Acid (EDTA) as anticoagulant. The samples were investigated for the following haematological parameters; Total Erythrocyte Count (TEC), Haemoglobin content (Hb), Packed Cell Volume (PCV) and White Blood Cell count (WBC) as stated in the method of Campbell (1998).

Biochemical parameters of blood

Blood samples were collected from the wing vein of birds from both the control and the treated groups (six birds from each group) before initiation and 21 days after the initiation of the experimental trial. Serum was separated and stored at -20°C until analysis. The samples were investigated for the following biochemical parameters; Total proteins, albumin, globulin, calcium, phosphorus, potassium and enzymes like Aspartate Amino Transferase (AST), Alanine amino Transferase (ALT) and Alkaline Phosphatase (ALP) in UV-VIS double beam spectrophotometer (Systronics, Model 2202, India)

Ethical approval

Approval was given by the local advisory committee members of the Post Graduate Diploma in Ethno Veterinary practices course of Tamil Nadu Veterinary and Animal Sciences University, Chennai, India.

Statistical analysis

The least mean square was analysed on the data collected on various parameters and the significant difference was estimated by the Duncan's Multiple Range test using SPSS 20.0 software. P values less than 0.05 were reported as statistically significant.

RESULTS AND DISCUSSION

The present work involving the supplementation of herbal preparation to assess its effect on haematology and serum biochemistry in layer chicken at 11-14 weeks of age (growers) was carried out in field conditions to look for the alternative phytobiotic growth promoting substances in improving health and production, without any issues of drug - residues and antimicrobial resistance.

Haematological parameters

The effect of the herbal preparations on haematological parameters is presented in the table 2 and figure1.

The mean Hb (gram %) is significantly ($P < 0.05$) increased in all the treatment groups including the control group (after initiation) than the control group (before initiation). Hence the treatment does not have any influence on Hb level in the bird's body. The mean RBC ($\times 10^6/\text{cu.}\mu\text{l}$) and the mean WBC ($\times 10^6/\text{cu.}\mu\text{l}$) count was also found to be significantly ($P < 0.05$) increased in the treatment groups suggesting that the herbal preparation is found to stimulate RBC production at a slightly increased level of supplementation. Similarly PCV (%) was

significantly increased in the groups II and III than the control groups.

There is no significant difference ($P < 0.05$) in heterophils (%) value, lymphocytes (%) value, monocytes (%) value, eosinophil (%) value and basophil (%) value between the control groups and the treatment groups.

Blood biochemistry

The effect of the herbal preparations on the blood biochemistry is presented in the table 3 and figure 2.

The total protein content (g/dl), albumin content and the globulin content of the treatment groups were significantly increased when compared with the control groups (before and after initiation). However globulin content in is not significantly higher than the control.

The glucose content in Group I is significantly ($P < 0.05$) reduced and Group III is significantly ($P < 0.05$) increased than the control group. The calcium (mg) in treatment groups was comparatively higher than the control groups. The phosphorus (mg) in Group I was significantly ($P < 0.05$) higher than the control groups. There is no significant ($P < 0.05$) difference in potassium (m.equ) between the treatment groups and the control groups. The enzyme ALT (U/L) is significantly ($P < 0.05$) increased in group I and group III than the other groups. The enzymes AST (U/L) and ALP (U/L) is significantly ($P < 0.05$) reduced in the treatment groups than the control groups.

Table 1. Regular feed composition for layers (11-14 weeks)

Ingredients	Quantity (Kg)
Maize	600
Pellet SF(36%) protein	97
Soya bean meal	150
Deoiled rice bran	115
Calcite	15
Dicalcium Phosphate	12
Salt	4
Soda bicarbonate	1
DL methionine	1
Lysine	0.9
Choline chloride	1
Vitamins	500 gram
Traceminerals	1 kg
Phytase	100 gram
Toxin binder	1 kg
Liver powder	500 gram

Protein = 17.25%; Energy = 2700Kcal

Table 2. Effect of the herbal preparations on the haematological parameters in layer chicken aged 11 -14 weeks (n=6)

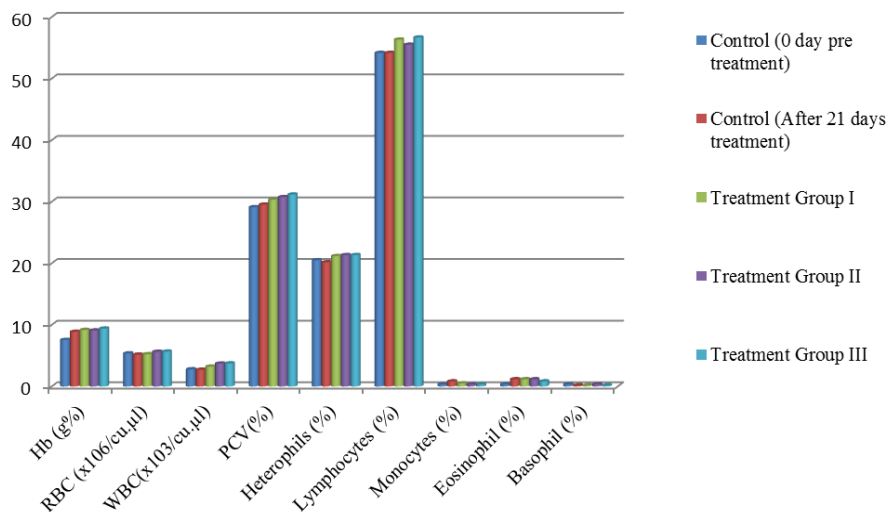
Variables	Treatment (Mean±SE)				
	Control (Days)		Group I	Group II	Group III
	Pretreatment at day 0 (samples from all the groups)	After 21 days treatment period (Control group)			
Hb (g%)	7.55 ± 0.29 ^{a*}	8.88 ± 0.19 ^b	9.18 ± 0.83 ^b	9.10 ± 0.03 ^b	9.4 ± 0.05 ^b
RBC (x10 ⁶ /cu.µl)	5.37 ± 0.09 ^a	5.17 ± 0.05 ^a	5.23 ± 0.03 ^a	5.63 ± 0.09 ^b	5.66 ± 0.12 ^b
WBC (x10 ³ /cu.µl)	2.78 ± 0.15 ^a	2.72 ± 0.25 ^a	3.22 ± 0.11 ^b	3.72 ± 0.14 ^c	3.75 ± 0.11 ^c
PCV (%)	29.11 ± 0.80 ^{ab}	29.53 ± 0.72 ^a	30.33 ± 0.80 ^{ab}	30.75 ± 0.51 ^c	31.17 ± 0.49 ^c
Heterophils (%)	20.5 ± 0.43 ^a	20.17 ± 0.48 ^a	21.17 ± 0.60 ^a	21.33 ± 0.95 ^a	21.33 ± 0.62 ^a
Lymphocytes (%)	54.16 ± 0.60 ^a	54.17 ± 0.60 ^a	56.33 ± 1.23 ^a	55.50 ± 1.65 ^a	56.67 ± 1.12 ^a
Monocytes (%)	0.33 ± 0.21 ^a	0.83 ± 0.31 ^b	0.50 ± 0.31 ^b	0.33 ± 0.17 ^b	0.33 ± 0.17 ^{ab}
Eosinophil (%)	0.33 ± 0.21 ^a	1.17 ± 0.17 ^a	1.17 ± 0.22 ^a	1.17 ± 0.21 ^a	0.83 ± 0.21 ^a
Basophil (%)	0.33 ± 0.21 ^a	0.17 ± 0.17 ^a	0.17 ± 0.17 ^a	0.33 ± 0.21 ^a	0.17 ± 0.17 ^a

*Mean values within the same row with different superscripts differ significantly (P<0.05)

Table 3. Effect of the herbal preparations on the blood biochemical parameters in layer chicken aged 11 -14 weeks (n=6)

Variables	Treatment (Mean±SE)				
	Control (Days)		Group I	Group II	Group III
	Pretreatment at day 0 (samples from all the groups)	After 21 days treatment period (Control group)			
Total Protein (g/dl)	3.31 ^a ± 0.17 [*]	3.58 ± 0.03 ^a	4.69 ± 0.02 ^b	5.21 ± 0.03 ^c	4.56 ± 0.11 ^b
Albumin (g%)	1.75 ± 0.07 ^a	1.84 ± 0.08 ^a	2.71 ± 0.01 ^b	2.75 ± 0.01 ^b	2.23 ± 0.01 ^c
Globulin (g%)	1.56 ± 0.22 ^a	1.74 ± 0.09 ^{ab}	1.97 ± 0.02 ^b	2.46 ± 0.03 ^c	2.33 ± 0.11 ^c
Glucose (mg%)	150.28 ± 0.87 ^a	153.12 ± 0.39 ^b	134.26 ± 0.10 ^c	149.23 ± 0.19 ^a	168.41 ± 0.18 ^d
Calcium (mg)	8.21 ± 0.10 ^a	8.64 ± 0.03 ^b	9.98 ± 0.03 ^c	10.67 ± 0.01 ^d	11.39 ± 0.08 ^e
Phosphorus (mg)	4.66 ± 0.12 ^{ab}	4.88 ± 0.06 ^b	5.18 ± 0.03 ^c	4.69 ± 0.13 ^{ab}	4.56 ± 0.04 ^a
Potassium (m.equ)	9.44 ± 0.12 ^{ab}	8.31 ± 1.59 ^a	10.90 ± 0.01 ^b	11.60 ± 0.21 ^b	10.72 ± 0.11 ^b
Aspartate aminotransferase (U/L)	222.72 ± 1.14 ^a	223.49 ± 0.14 ^a	189.24 ± 0.33 ^b	183.91 ± 0.30 ^c	182.33 ± 0.35 ^c
Alanine aminotransferase (U/L)	7.68 ± 0.11 ^a	7.46 ± 0.12 ^a	9.26 ± 0.06 ^b	7.73 ± 0.05 ^a	9.51 ± 0.16 ^b
Alkaline phosphatase (U/L)	229.17 ± 7.83 ^a	248.03 ± 1.24 ^b	195.22 ± 1.11 ^c	188.31 ± 0.53 ^c	207.34 ± 1.70 ^d

*Mean values within the same row with different superscripts differ significantly (P<0.05)

**Figure 1.** Effect of the herbal preparations on the haematological parameters in layer chicken aged 11 -14 weeks

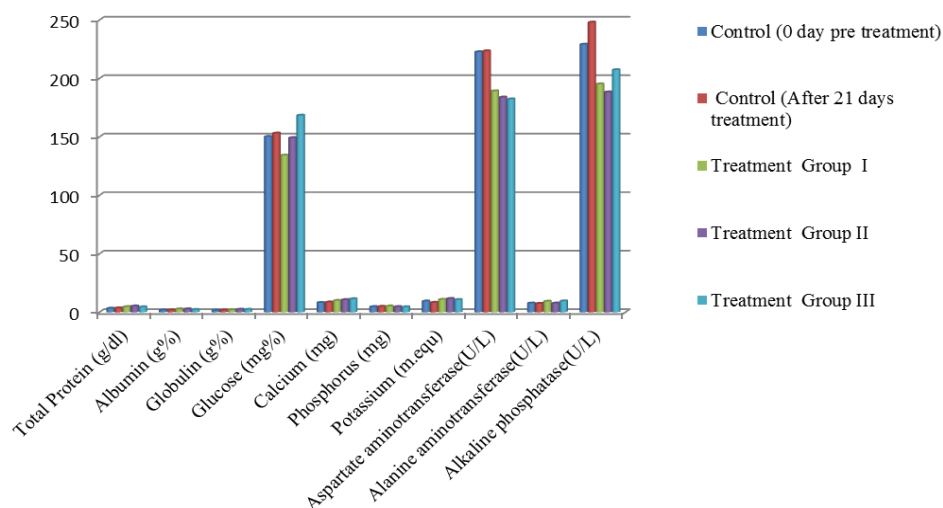


Figure 2. Effect of the herbal preparations on the blood biochemical parameters in layer chicken aged 11 -14 weeks

Our findings determined significant increase in RBC, white blood cells and PCV which are comparable with the findings of Vivian et al. (2015), Ajit et al. (2012) and Mitruka and Rawnsley (1977) who opined that that the increase in the vital hematological constituents like PCV, Hb, RBC, and WBC in birds fed with the herbal ingredients ginger, garlic and tulsi is an indication of improved oxygen carrying capacity of the cells which translated to a better availability of nutrients for utilization to the birds consequently affecting their well being with an active immune system. Gole (2001) reported an increase in total leukocyte count in broilers supplemented with 1% *Ocimum sanctum* and liquid preparation of vitamin E and Se. The non significant increase of haemoglobin with the value falling within the normal range is in accordance with the results of Onu et al. (2010) who observed similar results on feeding ginger and garlic to broiler and with the findings of Kolte (1993) who reported significant increase in Hb% in the broilers fed on *Ocimum sanctum* @ 4gm/ of feed in the diet. All the haematological indices were within safety limits in this experiment. The normal PCV, Hb, WBC and with differential count of the white blood cells in the normal range is similar to the findings of Thange (2009) who observed non-significant effect of *Ocimum sanctum* and other herbal preparation on monocytes, lymphocytes, esinophils and heterophils. The normal values of the haematological indices indicate the nutritional status of the grower chicken and thus the adequate nourishment of the birds as reported by Church et al. (1984) in his study. This implies that the immune system of the birds was also functioning adequately. The numerical differences observed in haematological indices with the test ingredients supplemented diets suggest that

the diets were better utilized and assimilated into the blood stream for use by the birds. There were also no sign of anemia or ill-health as the degree of anemia is determined by Hb, PCV, and RBC count which were in the normal range in the entire course of the experiment. Thus our findings strongly agree with Nagalakshmi et al. (1996) and Gowda et al. (1998) who reported that bitter principles of medicinal plants possess a strong influence on haematological traits depending on their nutritional status.

The increased content of total protein, albumin, globulin, calcium, phosphorus and with decreased levels of enzymes AST, ALP with other paramaters within the normal range is in agreement with the findings of Zhang et al. (2009) who found higher total protein concentration at 21 and 42 days of age in broilers fed with ginger powder and also in accordance with Goerge et al. (2015) and Tietz (1976). According to Awosanya et al. (1999) blood protein depends on the quality and quantity of dietary protein available in the feed. Thus the quality and quantity of the dietary proteins were nutritionally adequate on adding these herbal test ingredients and there was no alteration of normal systemic protein utilization and there is no sign of anaemia in the groups as the total protein was in the normal range (Siegmund, 1973). The present results of increased total protein and significant increase in globulin in the test groups as compared to control, match with those obtained in broiler chicks (Abdo and Zeinb, 2004) to citric acid and acetic acid inclusion, respectively. These results indicate that supplemented herbal ingredients may improve the immune response as globulin level has been used as an indicator of immune responses and source of antibody production. El-Kerdawy (1996) stated that high globulin level signify better disease resistance and immune

response. This result is in harmony with those of (Rahmani and Speer, 2005) who found higher percentage of gamma globulin in broilers given organic acids than the control ones. Thus the enhancement of immune response associated with dietary acidification could be due to the inhibitory effects of the herbal ingredients against the pathogenic microorganisms throughout the GI-tract.

The increase of Ca and P levels in blood serum produced by addition of herbs may be attributed to the lowering of GI-tract pH by using these herbal ingredients, which increases the absorption of such minerals from the gut into the blood stream. Improving the utilization of calcium and phosphorus is in accordance with the findings of Boling et al. (2001) who noticed similar results on supplementing organic acids. Also, Abdo and Zeinb (2004) observed an increase in blood calcium of broiler chicks fed on dietary acidifier.

The reduction in the enzyme levels AST and ALP indicate the hepatoprotective nature of the herbal preparation as the plant extract could repair the hepatic injury and/or restore the cellular permeability thus reducing the liver toxicity and preventing enzyme leakage into the blood circulation (Mathivanan and Edwin, 2012) and proves that the herbal test ingredients are not toxic (Toppo et al. 2009; Ali and Ismail, 2012; Qureshi et al., 2015) to the birds on oral feeding and could tolerate the addition of the herbal ingredients at the dose of 0.5% without any deleterious effects on liver functions. These results are in full agreement with Abdel-Azeem et al. (2000) who observed reduced AST although ALT was not significantly affected.

Many researchers found that garlic exhibits hypoglycemic effect and proposed that garlic can act as anti-diabetic agent by either increasing the pancreatic secretion of insulin from beta cells or its release from bound insulin (Jain and Vyas, 1975). The principal active ingredients in garlic are believed to be allyl propyl disulphide and diallyl disulphide oxide (allicin). Abdul-Rahman (2012), Safaei et al. (2013) and Mamoun et al. (2014) reported that incorporation of dietary fenugreek seeds in broilers at 1% level significantly decreased the blood glucose levels. The reduction in the serum glucose levels may be related to direct β -cell stimulation by amino acid (4-hydroxy isoleucine) which increases insulin secretion thus improves glucose tolerance when fenugreek seeds are fed (Sauvaire et al., 1998; Schryver, 2002). Grodsky et al. (1965) found that there may be substances that cause antagonistic effect between garlic and natural insulin and such antagonistic action might have occurred in this experiment as there was significant increase of glucose in the higher dose group.

Thus the increased glucose in the higher dose group with increased ALT, both the values within the normal range with some discrepancies in the results may be due to the differences in the dose levels as well as the experimental period and the experimental conditions.

CONCLUSION

It can be concluded that supplementation of the herbs *Ocimum sanctum* (Tulsi), *Allium sativum* (Garlic), *Curcuma longa* (curcumin), *Trigonella foenum graecum* (Fenugreek) and *Zingiber officinale* (ginger) could be important to improve layer performance as it is able to improve the immunity in the birds and increase the utilization of minerals required for an ideal production. The birds were found in a good health with no signs of anaemia which revealed the valuable and significant effects of these herbs.

Acknowledgements

This work was supported by a private farm at Namakkal district. Hence the authors are highly thankful to the owner of the farm.

Competing interests

The authors have no competing interests to declare.

Consent to publish

The authors consent to publish the work.

Author's contribution

All authors contributed significantly and equally in present article.

REFERENCES

- Abdel-Rahman HA, Fathallah SI and Helal AA (2014). Effect of Turmeric (*Curcuma longa*), Fenugreek (*Trigonella foenum-graecum* L.) and/or bioflavonoid supplementation to the broiler chicks diet and drinking water on the growth performance and intestinal morphometric parameters. *Global Vet*, 12 (5): 627-635. DOI: 10.5829/idosi.gv.2014.12.05.83148
- Abdo M and Zeinb A (2004). Efficacy of acetic acid in improving the utilization of low protein-low energy broiler diets. *Egyptian Poultry Science*, 24: 123-141.
- Ajit S, Doley P, Neeraj and Prasad J (2014). Effect of dietary supplementation of tulsi (*Ocimum sanctum*) leaf powder on haematology and serum biochemistry

- of broiler chicks. *International Journal of Biological and Pharmaceutical Research*, 5 (1): 89 - 92.
- Ali AHH and Ismail ZSH (2012). Some physiological changes related to *Fenugreek* seeds supplementation to broiler chick's diet. *Egyptian Journal of Nutrition and feeds*, 15: 95-104. DOI: 10.3923/ijps.2015.664.669
- Ashish RS, Bajaj VK, Sekawat PS and Singh K (2013). Phytochemical estimation and antimicrobial activity of aqueous and methanolic extract of *Ocimum Sanctum* L. *Journal of Natural product and Plant Resources*, 3 (1): 51-58.
- Awosanya B, Joseph JR, Apata DF and Agbola MA (1999). Performance, blood chemistry and carcass quality attributes of rabbits fed raw and processed pueraria seed meal. *Tropical Journal of Animal Science*, 2(2): 89-96.
- Ayasan (2013). Effects of dietary inclusion of protexin (probiotic) on hatchability of Japanese Quails. *Indian Journal of Animal Science*, 83 (1): 78-81. <https://www.researchgate.net/publication/287696519>
- Basu SK, Acharya SN, Bandara MS, Friebel D and Thomas JE (2009). Effects of genotype and environment on seed and forage yield in fenugreek (*Trigonella foenum-graecum* L.) grown in western Canada. *Australian Journal of Crop Science, Southern Cross Journals*, 3 (6): 305-14. <https://pdfs.semanticscholar.org>
- Bhargava S, Dhabhai K, Batra A, Sharma A and Malhotra B (2012). *Zingiber officinale*: Chemical and phytochemical screening and evaluation of its antimicrobial activities. *Journal of Chemical and Pharmaceutical Research*, 4 (1): 360-364. <http://www.jocpr.com>
- Boling SD, Frankenbach JL, Snow CM, Parsons and Baker DH (2001). The effect of citric acid on the calcium and phosphorus requirements of chicks fed Corn - soybean meal diets. *Poultry science*, 80: 783-788. <https://oup.silverchair-cdn.com>
- Cardelle CA, Soria AC, Martinez MC and Villamiel M (2010). A comprehensive survey of garlic functionality. In: *Garlic consumption and Health*. Chapter 1, pp 1-60. <http://digital.csic.es/bitstream>
- Church JP, Judd JT, Yomg CW, Kebay TL and Kim WW (1984). Relationship among dietary constituents and specific serum clinical components of subjects eating self selected diets. *America Journal Clinical Nutrition*, 40: 1338- 1344.
- Deshmukh M V (2014). Investigation of antibacterial potential of turmeric (*Curcuma longa*) on enteric pathogens. *International Journal of Applied Research*, 4 (12): 556-558. <https://www.worldwidejournals.com>
- El-Kerdawy DMA (1996). Acidified feed for growing rabbits. *Egyptian Journal of Rabbit Science*, 6 (2): 143-156. <http://easterplanet.ca/>
- Gabriel I, Lessire M, Mallet S and Guillot JF (2006). Microflora of the digestive tract : Critical factors and consequences for poultry. *World's Poultry Science Journal*, 62:499–511.
- Gatne MM, Patil R, Ravikanth K, Shivi M and Rekle DS (2010). Evaluation of immunomodulatory effect of Stresroak premix in broiler chick. *Veterinary world*, 3 (3): 122-125. <http://www.veterinaryworld.org>
- George OS, Kaegon SG and Igbokwe AA (2015). Feed additive effects of graded levels of ginger (*zingiber officinale*) on serum metabolites of broilers. *Journal of Agriculture and veterinary Sciences*, 8 (3): 59 – 62. <http://www.iosrjournals.org>
- Gole MA (2001). Effect of liquid preparation of vitamin E and Selenium on growth and immune response of broilers. M.V.Sc. thesis submitted to Dr. Balasaheb Sawant Konkan Krishi Vidyapeeth, Dapoli.
- Gowda SK, Verma SVS, Elangovan AV and Singh AD (1998). Neem (*Azadirachta indica*) kernel meal in the diet of white leghorn layer. *British Poultry Science*, 39(5): 648-652. <https://www.ncbi.nlm.nih.gov>
- Grodsky GM, Karam JH and Forsham PH (1965). Production of autoantibodies to insulin in man and rabbits. *Diabetes*, 14: 396-403. <https://www.ncbi.nlm.nih.gov>
- Jain RC and Vyas CR (1975). Garlic in alloxan induced diabetic rabbits. *American Journal of Clinical Nutrition*, 28 (7):684-685. <https://www.ncbi.nlm.nih.gov>
- Janardhana V, Broadway MM, Bruce MP, Lowenthal JW, Geier MS, Hughes RJ and Bean AGD (2009). Prebiotics modulate immune responses in the gut-associated lymphoid tissues of chickens. *Journal of Nutrition*, 139 (7): 1404-1409. DOI: 10.3945/jn.109.105007
- Jeurissen SH, Lewis F, Van der Klis JD, Mroz Z , Rebel JM and Ter Huurne AA (2002). Parameters and techniques to determine intestinal health of poultry as constituted by immunity, integrity, and functionality. *Current Issues in Intestinal Microbiology*, 3: 1–14. <http://www.scirp.org> ; ReferenceID=1733591
- Jinsuklee (2004). Medicinal Plants. A powerful health aid, Science creative quarterly. <http://www.seq.ubc.ca/medicinal-plants-a-powerful-health-aid/>, retrived on 15.04.13.

<http://www.scq.ubc.ca/medicinal-plants-a-powerful-health-aid/>

- Kabir SML (2009). The role of probiotics in the poultry industry. *International Journal of Molecular sciences*, 10(8): 3531- 3546. DOI: 10.3390/ijms10083531
- Kolte MV (1993). Effect of *Ocimum sanctum* linn., *Pyllanthus niruri* linn and active haematology, metabolic profile and immune response in goats. M. V. Sc., Thesis. (Unpub) Submitted to Dr. PDKV, Akola.
- Mamoun T, Mukhtar A and Mohamed HT (2014). Effect of Fenugreek seed powder on the Performance, Carcass Characteristics and Some Blood Serum Attributes. *Advance Research in Agriculture and Veterinary Science*, 1(1) : 6-11. <http://www.aravsjournal.com>
- Mathivanan R and Edwin SC (2012). Haematological and serum biochemical parameters of broilers fed with *Andrographis paniculata* as an alternative to antibiotic growth promoter. *Journal of Medicinal Plants Research*, 64 (44): 5647-5650
- Mitruka BM, Rawnsley HM, Vadehra BV (1977). Clinical biochemical and haematological reference values in normal experimental animals. Masson Publishing USA Inc. 272.
- Nagalakshmi D, Sastry VRB, Agrawal RC, Ketiyar DK and Verma SVS (1996). Performance of broiler chicks fed on alkali treated (*Azadirachta indica*) kernel cake as a protein supplement. *British Poultry Science*, 37 (4):809-818. DOI: 10.1080/00071669608417910
- Onu PN (2010). Evaluation of two herbal spices as feed additives for finisher broilers. *Biotechnology in Animal Husbandry*, 26 (5-6): 383-392. DOI: <http://dx.doi.org/10.2298/BAH1006383O>
- Pirgozliev V, Murphy TC, Owens B, George J and Mccann MEE (2008). Fumaric and sorbic acid as additives in broiler feed. *Research in Veterinary Science*, 84 (3):387-394. <https://www.ncbi.nlm.nih.gov>
- Qureshi S, Banday MT, Adil S, Shakeel I and Munshi ZH (2015). Effect of dandelion leaves and fenugreek seeds with or without enzyme addition on performance and blood biochemistry of broiler chicken and evaluation of their *in vitro* antibacterial activity. *Indian Journal of Animal Science*, 85 (11): 1248-1254. <https://www.researchgate.net/publication/287329961>
- Rahmani HR and Speer W (2005). Natural additives influence the performance and humoral immunity of broilers. *International Journal of Poultry Science*, 4 (9): 713-717. <http://agris.fao.org/ID=DJ2012051528>
- Reuter HD, Koch HP and Lawson LD (1996). Therapeutic effects and applications of garlic and its preparations. In: *Garlic: The science and therapeutic application of Allium sativum L. and Related Species*, Koch, H.P. and L.D. Lawson (Eds.). Williams and Wilkins, Baltimore, MD, 135 - 213.
- Rivlin RS (2001). Historical perspective on the use of garlic. *Journal of Nutrition*, 131 (35): 957 -954.
- Safaei A, Rahanjam SM and Gharajanlu M (2013). Effect of *Trigonella foenum-graecum* on immune response and some blood parameters of broilers. *Scholarly Journal of Agricultural Science* Vol. 3(4): 117-120. <http://www.scholarly-journals.com/SJAS>
- Sauvaire Y, Petit P and Broca C (1998). 4-Hydroxyisoleucine, A novel amino acid potentiator of Insulin secretion. *S Diabetes*, 47 (2): 206-210.
- Schryver T (2002). *Fenugreek*. *Total Health*, 24 (4): 42-44.
- Shukla ST, Kulkarni VH, Habbu PV, Jagadeesh KS, Patil BS and Smita DM (2012). Hepatoprotective and antioxidant activities of crude fractions of endophytic fungi of *Ocimum sanctum* Linn. in rats. *Oriental Pharmacy and Experimental Medicine*, 12 (2): 81-91. DOI: 10.1007/s13596-012-0061-7
- Siegmund OH (1973). The Merck veterinary manual, 4th Ed., Merck & Co. INC., Rahway, N.J., USA.
- Sojoudi MR, Dadashbeiki M and Bouyeh M (2012). Effects of different levels of symbiotic TechnoMos on broiler performance. *Research Opinions in Animal and Veterinary Sciences*, 2(4), 243-248. <https://www.researchgate.net>
- SPSS (2009). Computer software SPSS Inc. Headquarters, Wacker Drive, Chicago, Illinois-U.S.A.
- Thange HP(2009). Efficacy of different herbal preparation in broiler diet for immunomodulation. Thesis submitted to Maharashtra Animal and Fishery Sciences University, Nagpur.
- Thatte UM and Dhakanukar SA (1989). Immunotherapeutic modification of experimental infection by Indian medicinal Plants. *Phytotherapy Research*, 3: 43 - 49.
- Tietz NW (1976). *Fundamentals of clinical chemistry*, 2nd edition.W.B. Saunders Company Ltd., Philadelphia.pp.246.
- Tipu MA, Akhtar MS, Anjum MI and Raja ML (2006). New dimensions of medicinal plants as animal feed. *Pakistan Veterinary Journal*, 26(3): 144-148. <http://pvj.com.pk>
- Toppo FA, Rachna A and Pathak AK (2009). Pharmacological actions and potential uses of *Trigonella foenum graecum*: A Review. *Asian Journal of Pharmaceutical and Clinical Research*, 2 (4): 69-74. <http://ajpcr.com>
- Vijayalakshmi K, Priya V and Jananic RK (2011). GC/MS determination of bioactive components of *Trigonella*

- foenum grecum*. Journal of chemical and pharmaceutical Research, 3(5): 35 -40.
- Virupaksha JH, Shivakumar H and Jayakumar BHMS (2007). Evaluation of anti-diarrhoeal activity of fenugreek seed extracts in rats. Pharmacologyonline., 2; 255- 266. <http://pharmacologyonline.silae.it/>
- Vivian UOO, Ndofor-Foleng HM, Olorunleke SO and Uguru JO (2015). Evaluation of growth performance, haematological and serum biochemical response of broiler chickens to aqueous extract of ginger and garlic. Journal of Agricultural Sciences, 7 (4): 167 - 173. <http://citeseerx.ist.psu.edu>
- Yang Y, Iji PA, Kocher A, Thomson E, Mikkelsen LL and Chot M (2008). Effects of mannanoligosaccharide in broiler chicken diets on growth performance, energy utilization, nutrient digestibility and intestinal microflora. British Poultry Science, 49: 186-194.
- Yang Y, Iji PA and Choct M (2009). Dietary modulation of gut microflora in broiler chickens: a review of the role of six kinds of alternatives to in-feed antibiotics. World Poultry Science Journal, 65 pp. 97 - 114. DOI:10.1017/S0043933909000008
- Zhang GF, Yang ZB, Wang Y, Yang WR, Ziang SZ and Gai GS (2009). Effects of Ginger root (*Zingiber officinale*) processed to different particle sizes on growth performance, antioxidant status and serum metabolites of broiler chickens. Poultry science, 88: 2159 - 2166. DOI: 10.3382/ps.2009-00165.