



# Isolation and Identification of *Eimeria* spp. From Domestic Pigeons (*Columba livia domestica*) in Basrah, Iraq

Alaa Ismail Saood<sup>1</sup> , Isam Azeez Khaleefah<sup>2</sup> , Khawla Bedan Nassir Aljassim<sup>3</sup> , Sara Salim Mohammad<sup>4</sup> ,  
Abduljabbar Khadim Alkinani<sup>3</sup> , and Harith Abdulla Najem<sup>2\*</sup>

<sup>1</sup>Department of Veterinary Parasitology, College of Veterinary Medicine, University of Basrah, Basrah, Iraq

<sup>2</sup>Department of Pathology and Poultry Diseases, College of Veterinary Medicine, University of Basrah, Iraq

<sup>3</sup>Veterinary Hospital, Basrah, Iraq

<sup>4</sup>Department of Veterinary Public Health, College of Veterinary Medicine, University of Basrah, Basrah, Iraq

\*Corresponding author's E-mail: [harith.najem@uobasrah.edu.iq](mailto:harith.najem@uobasrah.edu.iq)

Received: July 08, 2025, Revised: August 12, 2025, Accepted: September 04, 2025, Published: September 25, 2025



## ABSTRACT

Coccidiosis is a widespread disease among pigeons worldwide, resulting in significant economic losses due to mortality, morbidity, and reduced feed efficiency. The present study aimed to isolate a field strain of *Eimeria* spp. in domestic pigeons (*Columba livia domestica*) in Basra, Iraq. To ensure precise species identification, light microscopy techniques were combined with the advanced molecular method of polymerase chain reaction (PCR). Sixty fresh fecal samples were collected from pigeon lofts, ensuring minimal environmental disturbance and contamination. The flotation method was employed to analyze fecal samples. The present results indicated that 36 out of 60 samples contained coccidian oocysts, which represented an overall prevalence of 60%. The PCR technique was employed to amplify the *18S rRNA* genes, which were subsequently utilized for sample detection. Six representative sequences were selected, registered, and deposited in the NCBI database (PV459631.1, PV459632.1, PV459633.1, PV459634.1, PV459635.1, and PV459636.1). The present findings were validated through molecular analysis, and six representative gene sequences were submitted to the National Centre for Biotechnology Information (NCBI) database. The current study revealed a high prevalence of coccidiosis, affecting 60% of domestic pigeons in Basra, highlighting its impact on their health. Moreover, this is the first report of *Eimeria chalcopterae* in pigeons from Basra, Iraq.

**Keywords:** *Eimeria chalcopterae*, Molecular technique, Phylogeny, Pigeon

## INTRODUCTION

Coccidiosis is a prevalent disease among pigeons globally and results in considerable economic losses due to mortality, illness, and diminished feed efficiency (Santos et al., 2020; Aboelhadid et al., 2021). The performance of poultry is adversely affected by this condition as it induces acute disease and impairs nutritional utilization (Al-Agouri et al., 2021). Coccidiosis is a significant veterinary

disease with a notable economic impact on the pigeon industry (He et al., 2024).

The signs of coccidiosis include watery diarrhoea accompanied by mucus (Mohammed et al., 2017). Watery diarrhea with mucus is a common sign of mucoid or bloody diarrhea, often associated with clinical features such as dysentery, enteritis, emaciation, decreased feed conversion, drooping wings, poor growth, and even death. This condition serves as one of the early diagnostic

indicators for avian coccidiosis (Ola-Fadunsin et al., 2017). Pigeons are infected by 21 species of intracellular apicomplexan protozoan parasites from the genus *Eimeria* (Albasyouni et al., 2024). To reduce the risk of parasite spread, regularly remove feces and clean cages and floors. Since coccidiosis spreads rapidly in crowded environments, preventing overcrowding in barns is essential, along with ensuring proper ventilation and humidity control in breeding areas. Additionally, a balanced diet supplemented with vitamins and immune-boosting nutrients such as A, E, and C is recommended (Alsayeqh and Abbas, 2023). Although management and biosecurity measures may potentially prevent the introduction of *Eimeria* spp. to a farm, in practice, these measures are insufficient to prevent outbreaks of coccidiosis. However, extensive and prolonged use of anticoccidial medicine has resulted in the development of resistance worldwide against all such medications (Peek and Landman, 2011). In Basra, Iraq, where pigeon breeding holds considerable cultural and economic importance, *Eimeria* spp. presents both health and economic difficulties. The present study aimed to isolate a field strain of *Eimeria* spp. in domestic pigeons (*Columba livia domestica*) of Basra, Iraq.

## MATERIALS AND METHODS

### Ethical approval

The Research Ethics Committee approved the experimental procedures and animal care. Research Ethics Committee No. 83/37/2025 from the University of Basrah-College of Veterinary Medicine confirms that all protocols were followed, and appropriate measures were taken to minimise discomfort.

### Study area and sample collection

The present study was conducted from April to December 2024. A total of 60 adult domestic pigeons (*Columba livia domestica*) from different lofts located in several areas of Basrah, Iraq, were included. All of the pigeons exhibited clinical signs of coccidiosis, including weight loss (Emaciation) and the presence of bloody droppings. There were no pigeons found without signs of coccidiosis. The number of pigeons per loft differed from 20 to 80, with some lofts experiencing substandard living conditions and inadequate provisions and sanitation.

### Fecal examination

Fecal samples of approximately 1 g were collected from each pigeon and placed in individual screw-capped plastic containers labelled appropriately. These samples

were subsequently transported to the Department of Veterinary Parasitology at the College of Veterinary Medicine, University of Basrah, Basrah, Iraq. Initially, the samples were examined to determine color, consistency, and the presence of blood, mucus, or other contaminants. The presence or absence of coccidia oocysts was checked using an Olympus microscope (Japan) with Sheather's sucrose solution. In positive samples, oocysts were concentrated via the flotation technique described by Alasadiy et al. (2022). Oocyst morphology and sporulation time were used to identify the species of *Eimeria* spp., following the guidelines outlined by Silva et al. (2022).

### Polymerase chain reaction amplification, DNA extraction, and sequencing

The DNA was obtained from the purified oocysts for molecular identification using a commercial DNA extraction kit. The *Eimeria* spp. *18S rRNA* gene was targeted by a polymerase chain reaction (PCR). The QIAamp PowerFecal Pro DNA Kit (Cat. No/ID: 51804, QIAGEN, Australia) was used to extract total DNA from 350 mg of each fecal sample, following the manufacturer's instructions. A nested PCR was conducted using the methods outlined by Yang et al. (2016a;b). An expected PCR product of approximately 1510 bp was anticipated. The primers EiGTF1 5'-TTCACAGGACCCTCCGATC and EIGTR1 5'-AACCATGGTAATTCTATGG were employed for the external amplification of the *18S rRNA* gene.

### Sequence and bioinformatics analysis

The positive PCR results were sequenced forward at the MacroGen® sequencing facility (Seoul, South Korea). The obtained sequences were verified using a BLAST search and a sequence identity for further analysis. Sequences were aligned with relevant reference sequences using the CLUSTAL-X approach (Thompson et al., 1997). The Tamura-Nei model was used for a comprehensive evaluation of taxonomic relationships based on nucleotide analysis, and phylogenetic trees were constructed using the maximum likelihood approach (Tamura et al., 2011).

## RESULTS

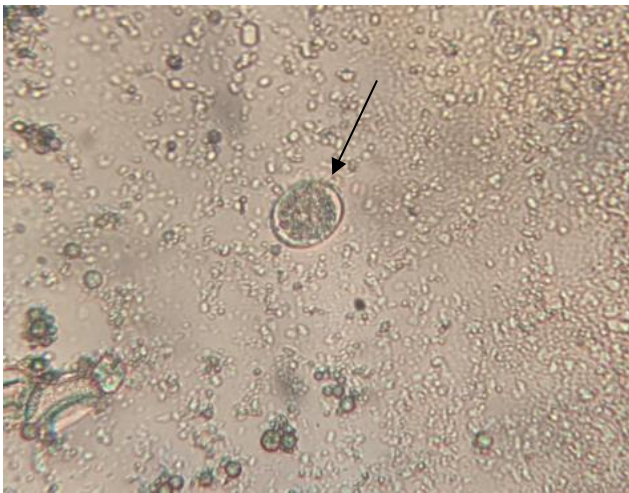
The total population of domestic pigeons was estimated at 60, with a 60% prevalence of coccidian infection, which was detected using the flotation technique. The oocyst was sub-spherical to spherical in shape and lacked a micropyle. The wall was thick, smooth, and consisted of two layers. Sporulation occurred within 24 to 48 hours. An example of a non-sporulated oocyst is shown in Figure 1.

### Detection of DNA by the polymerase chain reaction

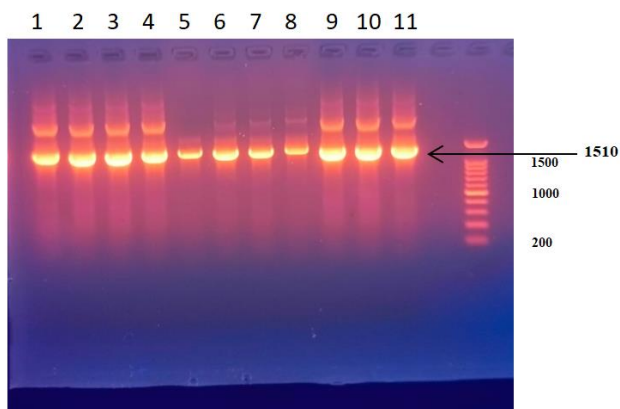
Polymerase chain reaction was employed to amplify the DNA extracted from *E. chalcoptereae* samples utilizing both forward and reverse primers. Subsequently, eleven samples were identified using PCR (Figure 2). The DNA bands, approximately 1510 base pairs in length, were observed after examination on an agarose gel.

### Phylogenetic analysis


According to the sequence analysis results, all six positive strains exhibited a proximate relationship. Six representative sequences were selected and uploaded to the NCBI database. The new records are labelled as PV459631.1, PV459632.1, PV459633.1, PV459634.1, PV459635.1, and PV459636.1. Figure 3 presents the phylogenetic trees, which depict the evolutionary links between pigeon *Eimeria* spp. from the NCBI database and strains isolated from pigeons in Basra, Iraq, marked by the red square.



**Figure 1.** The *Eimeria chalcoptereae* oocyst that is not sporulated (black arrow,  $\times 40$ ) isolated from a pigeon in Basrah, Iraq.



**Figure 2.** Polymerase chain reaction analysis of *Eimeria chalcoptereae* isolated from a pigeon in Basrah, Iraq, using agarose gel electrophoresis. M: 1510 bp molecular Ladder, Lane: Samples 1-11 were examined.



**Figure 3.** Phylogenetic tree analysis of six *Eimeria chalcoptereae* isolated from pigeons in Basrah, Iraq. It is constructed based on the *Eimeria chalcoptereae* small subunit ribosomal RNA gene, partial sequence, displaying the evolutionary relationships between closely related pigeon *Eimeria* spp. from the NCBI database and strains isolated from pigeons (red square). Utilizing MEGAX11 software, the neighbor-joining approach was used to create the tree and perform evolutionary studies.

### DISCUSSION

Based on the present results, numerous breeds of pigeons were bred in Basra, Iraq, for different purposes. According to the present study, 36 out of 60 samples tested positive for coccidian oocysts, indicating an overall incidence of 60%. This prevalence aligns with data from other countries, including 67.58% as documented by Gül et al. (2009) in Turkey, 56.2% as noted by Joseph et al. (2017) in Nigeria, 75% as reported by Ramesh et al. (2018) in India, 58.2% as observed by Elseify et al. (2018) in Egypt, and 52% as reported by Huang et al. (2018) in China. A reduction in food consumption, weakness, and greenish watery diarrhoea were the clinical manifestations of pigeon intestinal coccidiosis. Several studies have reported that coccidiosis causes significant losses in domestic pigeons (Dalloul and Lillehoj, 2005; Bandyopadhyay et al., 2006; Quiroz-Castañeda et al., 2015; Gadelhaq and Abdelaty, 2019). One of the limitations of microscopy is its inability to reliably discriminate across species. For increased sensitivity and species identification, previous studies have emphasized the importance of incorporating molecular diagnostics, such as PCR (Haug et al., 2008). In Al-Diwaniyah province, Iraq, Jawad and Jasim (2025) demonstrated that PCR-based diagnostics significantly enhanced the accuracy of identifying *E. tenella*, indicating its prevalence in broiler farms. The current findings highlighted the crucial role of molecular surveillance in poultry operations, particularly considering that

microscopic detection may underestimate the true level of infection, especially in subclinical cases. In the present study, PCR was employed to validate the initial clinical diagnosis, representing the initial effort to identify and isolate *Eimeria* spp. in Basra, Iraq. Phylogenetic trees are frequently employed to analyze *Eimeria* spp. in domestic pigeons in Basra, Iraq. Six representative sequences were selected, documented, and uploaded to the NCBI database (PV459631.1, PV459632.1, PV459633.1, PV459634.1, PV459635.1, and PV459636.1). In the current investigations, extremely small genetic differences were observed between the *E. chalcoptereae* isolates from Basra, Iraq, ranging from 0.000 to 0.004%, indicating a shared origin or local evolution, along with advantageous genetic conservation. The isolates from Basra and the reference strain of *E. chalcoptereae* (MT452662.2), as documented by Yang et al. (2020), exhibited pairwise genetic distances ranging from 0.007% to 0.009%, indicating a moderate level of divergence, likely due to regional or host-specific factors. It is inferred that the sequences identified in the present study and those documented by Yang et al. (2020) most likely correspond to the same species, as the present study and Yang et al. (2020) are currently the only sources of molecular data available. This is attributed to the role of Basra as a central hub for the illicit transportation of pigeons originating from Persian Gulf countries, despite these pigeons emanating from two distinct and geographically isolated regions (Al-Hasnawy and Rabee, 2023; Jaafar, 2023). Pairwise distances were notably greater, ranging from 0.008% to 0.021%, compared to other *Eimeria* spp., including *E. kofoidi* (MW934260.1), *E. innocua* (HG793045.1), *E. dispersa* (KT184338.1), and *E. purpureicephali* (KU140597.1). The current results confirmed the uniqueness of the *E. chalcoptereae* isolates found in Basra, Iraq, highlighting their differentiation at the species level. This phylogenetic analysis revealed that the isolates from Basra, Iraq, are genetically consistent and clearly distinct from other *Eimeria* spp. These findings have deepened the understanding of local parasite evolution and may guide future studies on host-pathogen interactions and control strategies.

## CONCLUSION

The current study revealed a high prevalence of coccidiosis, exceeding 60%, among domestic pigeons in Basra, Iraq. Molecular analysis identified 11 samples that amplified the 18S rRNA genes. *Eimeria chalcoptereae* was detected in *Columba livia domestica* pigeons, which

presented the first record of *Eimeria chalcoptereae* in Basra, Iraq. Six representative sequences were selected, registered, and deposited in the NCBI database (PV459631.1, PV459632.1, PV459633.1, PV459634.1, PV459635.1, and PV459636.1). To understand the distribution and genetic diversity of *Eimeria* spp., future studies should concentrate on seasonal infection patterns, their effects on productivity, and possible medication resistance. Additionally, molecular surveillance should be expanded throughout bird flocks in Iraq.

## DECLARATIONS

### Acknowledgments

The authors wish to acknowledge the Laboratory of the Department of Veterinary Parasitology at the College of Veterinary Medicine, University of Basrah, Basrah, Iraq.

### Authors' contributions

The study's conception and design, data collection, and analysis were all conducted by Alaa Ismail Saood, Isam Azeez Khaleefah, Sara Salim Mohammad, Abduljabbar Khadim Alkinani, Khawla Bedan Nassir Aljassim, and Harith Abdulla Najem. Abduljabbar Khadim Alkinani and Khawla Bedan Nassir Aljassim took part in sample processing and laboratory procedures. Harith Abdulla Najem and Sara Salim Mohammad assisted with the manuscript's development and critical review. Alaa Ismail Saood oversaw the study, created the graphical abstract, and completed the manuscript. The final draft of the manuscript was authorized for publication by all authors.

### Funding

This study did not receive any financial support or funding.

### Conflict of interests

The authors declared that they have no conflicts of interest.

### Ethical considerations

The authors are the original authors of this paper, which has not been published anywhere. The authors verified that their original scientific findings served as the basis for the article's writing by running it through a plagiarism index.

### Availability of data and materials

The corresponding author can provide the data supporting these findings upon reasonable request.



## REFERENCES

- Aboelhadid SM, Arafa WM, Abdelaty AS, Moawad UK, El Ashram S, and Gadelhaq SM (2021). Remarks on *Eimeria labbeana* infection in domestic pigeons, *Columba livia domestica*. Journal of Parasitic Diseases, 45(4): 1145-1151. DOI: <https://www.doi.org/10.1007/s12639-021-01411-z>
- Al-Agouri S, Alrwab NH, Amgawer HG, Sadaga G, and Alshelmani MI (2021). Prevalence of coccidia in domestic pigeons (*Columba livia domestica* Gmelin, 1789) in Benghazi city, Libya. Aceh Journal of Animal Science, 6(2): 52-56. DOI: <https://www.doi.org/10.13170/ajas.6.2.20374>
- Albasyouni S, Abdel-Gaber R, Al Quraishy S, Al-Shaebi EM, and Mohammed OB (2024). Morphology, morphometry, and phylogeny of the protozoan parasite, *Eimeria labbeana*-like (Apicomplexa, Eimeriidae), infecting *Columba livia domestica*. Frontiers in Veterinary Science, 11: 1392238. DOI: <https://www.doi.org/10.3389/fvets.2024.1392238>
- Al-Hasnawy MH and Rabee AH (2023). A review on *Trichomonas* species infection in humans and animals in Iraq. Iraqi Journal of Veterinary Sciences, 37(2): 305-313. DOI: <https://www.doi.org/10.33899/ijvs.2022.133966.2324>
- Alsayeqh AF and Abbas RZ (2023). Nutritional supplements for the control of avian coccidiosis – A review. Annals of Animal Sciences, 23(4): 993-1007. DOI: <https://www.doi.org/10.2478/aoas-2023-0013>
- Alasadi YDK, Mahmood RM, and Alhasnawi AN (2022). A comparative study of parasitic infections in domestic and wild pigeons in Iraq. Archives of Razi Institute, 77(2): 709-715. DOI: <https://www.doi.org/10.22092/ARI.2022.357105.1976>
- Bandyopadhyay PK, Bhakta JN, and Shukla R (2006). A new *Eimeria* species (Protozoa: Apicomplexa: Sporozoea) from the blue rock pigeon *Columba livia* (Aves: Columbidae). Zoos' Print Journal, 21(9): 2386-2387. DOI: <https://www.doi.org/10.11609/JoTT.ZPJ.1445.2386-7>
- Dalloul RA and Lillehoj HS (2005). Recent advances in immunomodulation and vaccination strategies against coccidiosis. Avian Diseases, 49(1): 1-8. DOI: <https://www.doi.org/10.1637/7306-11150R>
- Elseify MA, Metwally AM, Mahmoud SZ, and Abdelrheem EH (2018). Prevalence of coccidia infection among domestic pigeon (*Columba livia domestica*) and quails (*Coturnix ypsilophora*) in Qena province, Southern Egypt, Kafrelsheikh. Veterinary Medical Journal, 16(2): 1-21. DOI: <https://www.doi.org/10.21608/kvmj.2018.110173>
- Gadelhaq SM and Abdelaty AH (2019). The occurrence and distribution pattern of *Eimeria* species among domestic pigeons in Minia, Egypt. Journal of Veterinary Medical Research, 26(2): 164-173. DOI: <https://www.doi.org/10.21608/jvmr.2019.66098>
- Gül A, Özdal N, Değer S, and Denizhan V (2009). Van'da evcil güvercinlerde (*Columba livia domestica*) coccidia ve helminth türlerinin yayılışı [Prevalence of coccidia and helminth species in domestic pigeons (*Columba livia domestica*) in Van]. YYU Veteriner Fakültesi Dergisi, 20(2): 45-48. DOI: <https://www.doi.org/10.17094/yyuvfd.3651>
- Haug A, Gjevre AG, Thebo P, Mattsson JG, and Kaldhusdal M (2008). A survey of the economic impact of subclinical *Eimeria* infections in broilers in Norway. Avian Pathology, 37(4): 333-341. DOI: <https://www.doi.org/10.1080/03079450802050705>
- Huang D, Zhao Q, Han H, Jiang L, Zhu S, and Li T (2018). Prevalence of coccidial infection in dairy cattle in Shanghai, China. Journal of Parasitology, 98(5): 963-966. DOI: <https://www.doi.org/10.1645/GE-2966.1>
- Jaafar A (2023). Avian trichomoniasis prevalence in domesticated pigeons in Thi-Qar Province, Iraq. University of Thi-Qar Journal of Agricultural Research, 12(2): 89-108. DOI: <https://www.doi.org/10.54174/utjagr.v12i2.268>
- Jawad TI and Jasim GA (2025). Molecular detection and histopathological changes caused by *Eimeria tenella* in broilers in Al-Diwaniyah Province, Iraq. Open Veterinary Journal, 15(2): 714-723. DOI: <https://www.doi.org/10.5455/OVJ.2025.v15.i2.20>
- Joseph J, Wama BE, Aguzie ION, and Akwa VY (2017). Prevalence of coccidial infection in domesticated pigeon (*Columba livia domestica*) in Maiduguri Metropolis, Borno State, Nigeria. International Journal of Medical Sciences, 10(1 & 2): 25-28. DOI: <https://www.doi.org/10.15740/HAS/IJMS/10.1and2/25-28>
- Mohammed BR, Simon MK, Agbede RI, and Arzai AH (2017). Coccidiosis of domestic pigeons (*Columba livia domestica* Gmelin, 1789) in Kano State, Nigeria. Annals of Parasitology, 63(3): 199-203. DOI: <https://www.doi.org/10.17420/ap6303.106>
- Ola-Fadunsin GA, Adediran AO, and Iseh KR (2017). Investigations on the occurrence and associated risk factors of avian coccidiosis in Osun State, Southwestern Nigeria. Journal of Parasitology Research, 2017(1): 9264191. DOI: <https://www.doi.org/10.1155/2017/9264191>
- Peek HW and Landman WJM (2011). Coccidiosis in poultry: anticoccidial products, vaccines and other prevention strategies. Veterinary Quarterly, 31(3): 143-161. DOI: <https://www.doi.org/10.1080/01652176.2011.605247>
- Quiroz-Castañeda RE and Dantán-González E (2015). Control of avian coccidiosis: Future and present natural alternatives. Biomedical Research International, 2015: 430610. DOI: <https://www.doi.org/10.1155/2015/430610>
- Ramesh S, Soundararajan C, Subapriya S, Sokkalingam R, and Muthukrishnan S (2018). Incidence of coccidiosis in domestic pigeons (*Columba livia*) – A case report. International Journal of Current Microbiology and Applied Sciences, 6: 52-56. DOI: <https://www.doi.org/10.20546/ijcmas.2018.712.420>
- Santos HM, Tsai CY, Catulin GEM, Trangia KCG, Tayo LL, Liu HJ, and Chuang KP (2020). Common bacterial, viral, and parasitic diseases in pigeons (*Columba livia*): A review of diagnostic and treatment strategies. Veterinary Microbiology, 247: 108779. DOI: <https://www.doi.org/10.1016/j.vetmic.2020.108779>
- Silva JT, Alvares FB, Lima EF, Silva Filho GM, Silva AL, and Lima BA (2022). Prevalence and diversity of *Eimeria* spp. in free-range chickens in northeastern Brazil. Frontiers in Veterinary Science, 9: 1031330. DOI: <https://www.doi.org/10.3389/fvets.2022.1031330>

- Tamura K, Peterson D, Peterson N, Stecher G, Nei M, and Kumar S (2011). MEGA5: Molecular evolutionary genetics analysis using maximum likelihood, evolutionary distance, and maximum parsimony methods. *Molecular Biology and Evolution*, 28(10): 2731-2739. DOI: <https://www.doi.org/10.1093/molbev/msr121>
- Thompson JD, Gibson TJ, Plewniak F, Jeanmougin F, and Higgins DG (1997). The CLUSTAL\_X windows interface: flexible strategies for multiple sequence alignment aided by quality analysis tools. *Nucleic Acids Research*, 25(24): 4876-4882. DOI: <https://www.doi.org/10.1093/nar/25.24.4876>
- He X, Fang XM, Qiao YT, Su JL, Tang SQ, Weng YB, and Lin RQ (2024). Molecular identification and biological characterization of *Eimeria columbarum* from domestic pigeons (*Columba livia domestica*) in Guangdong, China. *Veterinary Quarterly*, 44(1): 1-11. DOI: <https://www.doi.org/10.1080/01652176.2024.2412297>
- Yang R, Brice B, Berto B, and Ryan UM (2020). Morphological and genetic characterization of *Eimeria chalcoptereae* n. spp. (Apicomplexa: Eimeriidae) in a common bronzewing pigeon (*Phaps chalcoptera*) (Latham, 1790) in Western Australia. *Parasitology Research*, 119: 3729-3737. DOI: <https://www.doi.org/10.1007/s00436-020-06844-8>
- Yang R, Brice B, Elloit A, and Ryan U (2016a). Morphological and molecular characterization of *Eimeria labbeana*-like (Apicomplexa: Eimeriidae) in a domestic pigeon (*Columba livia domestica*, Gmelin, 1789) in Australia. *Experimental Parasitology*, 166: 124-130. DOI: <https://www.doi.org/10.1016/j.exppara.2016.04.009>
- Yang R, Brice B, and Ryan U (2016b). Morphological and molecular characterization of *Isospora neochmiae* n. sp. in a captive-bred red-browed finch (*Neochmia temporalis*) (Latham, 1802). *Experimental Parasitology*, 166: 181-188. DOI: <https://www.doi.org/10.1016/j.exppara.2016.04.011>

**Publisher's note:** [Scienceline Publication](#) Ltd. remains neutral with regard to jurisdictional claims in published maps and institutional affiliations.



**Open Access:** This article is licensed under a Creative Commons Attribution 4.0 International License, which permits use, sharing, adaptation, distribution and reproduction in any medium or format, as long as you give appropriate credit to the original author(s) and the source, provide a link to the Creative Commons licence, and indicate if changes were made. The images or other third party material in this article are included in the article's Creative Commons licence, unless indicated otherwise in a credit line to the material. If material is not included in the article's Creative Commons licence and your intended use is not permitted by statutory regulation or exceeds the permitted use, you will need to obtain permission directly from the copyright holder. To view a copy of this licence, visit <https://creativecommons.org/licenses/by/4.0/>.